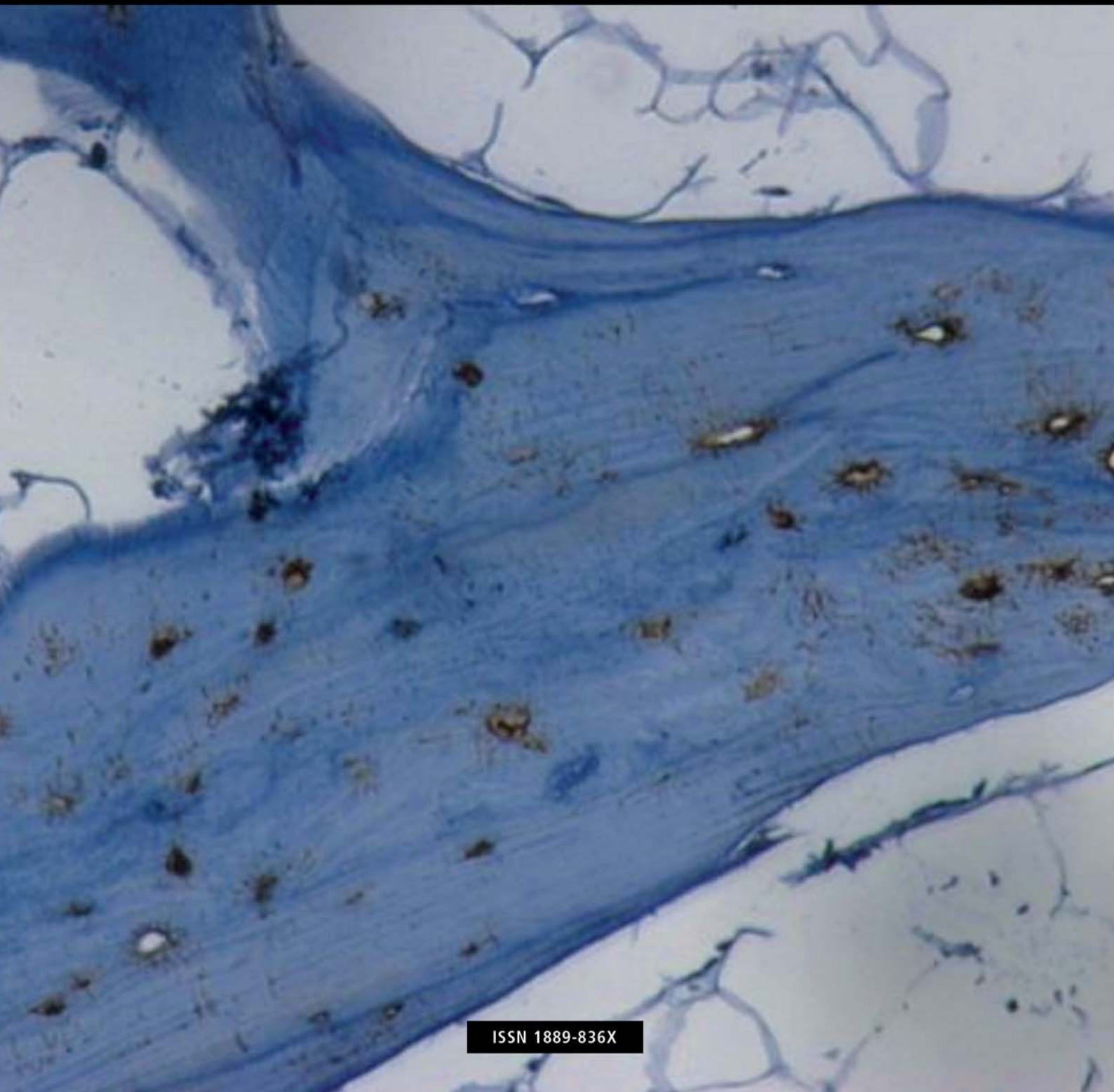



Volume 7 · Number 1 · January-March 2015

Revista de Osteoporosis y Metabolismo Mineral

www.revistadeosteoporosisymetabolismomineral.com





Our cover

Trebécula human bone stained with hematoxylin and an anti-sclerostin antibody reveals intense staining in the osteocytes and their extensions (brown)

Authors:

José A. Riancho and Jana Arozamena (Dpto. de Medicina Interna, Hospital Univ. Marqués de Valdecilla-Universidad de Cantabria-IDIVAL)

Director

Manuel Sosa Henríquez

Editor Head

M^a Jesús Gómez de Tejada Romero

Sociedad Española de Investigación Ósea y del Metabolismo Mineral (SEIOMM)

President

Francesc Xavier Nogués Solán

Vicepresident

José Manuel Olmos Martínez

Secretariat

Carmen Gómez Vaquero

Treasure

Arancha Rodríguez de Cortazar

Vocal 1

Cristina Carbonell Abella

Vocal 2

Antonio Cano Sánchez

Velázquez, 94 (1^a planta)
28006 Madrid (Spain)

Tel: +34-625 680 737

Fax: +34-917 817 020

e-mail: seiommm@seiommm.org

<http://www.seiommm.org>

Editing



Avda. Reina Victoria, 47 (6^o D)
28003 Madrid (Spain)

Tel. +34-915 538 297

e-mail: correo@ibanezyplaza.com

<http://www.ibanezyplaza.com>

Graphic design

Concha García García

English translation

Andrew Stephens

Impresion

Gráficas 82, S.L.

Valid Support

32/09-R-CM

Legal Deposit

M-3643-2013

ISSN 1889-836X

SUMMARY

Vol. 7 - Nº 1 - January-March 2015

5 EDITORIAL

Trabecular bone score and surgical treatment of primary hyperparathyroidism

Reyes García R, Muñoz-Torres M

6 ORIGINAL ARTICLE

A986S polymorphism of calcium-sensing receptor and osteoporotic clinical fractures

Briungos-Figuero LS, Abad-Manteca L, Cuadrado-Medina F, Pineda-Alonso M, Vega-Tejedor G, Pérez-Castrillón JL

11 CLINICAL NOTES

Melorheostosis: presentation of a clinical case

Suárez Bordón S, González González Y, Santana Borbones M, Herrera Henríquez J, Hernández Hernández D, Sosa Henríquez M

15 Are the current surgical criteria for asymptomatic primary hyperparathyroidism valid?

Fernández-SanMillán D, Santana Borbones A, Pérez Alonso E, Santana JR, Hernández Hernández D, Sosa Henríquez M

20 Familial hypocalciuric hypercalcemia: sometimes it is not what it seems

Merino M, Vega B, Guijarro G, Navea C, Torán C, Civantos S

23 Multiple osteonecrosis as a form of presentation of osteogenesis imperfecta

Lisa Gracia M, Córdoba Alonso AI, Pérez Núñez MI, Hernández Hernández JL

27 REVIEWS

Regulation of bone modifications in the mother during pregnancy

Sabonet-Morente L, Carrasco-Catena A, Castro A, González M, Cano A

33 Action of vitamin K on bone health

Díaz Curiel M

Indexed in: Scielo, IBECs, SIIC Data Bases, embase, Redalyc, Open J-Gate, DOAJ, Free Medical Journal, Google Academic, Medes, Electronic Journals Library AZB, e-revistas, WorldCat, Latindex, EBSCOhost, MedicLatina, Dialnet, SafetyLit, Mosby's, Encare, Academic Keys.

Submit originals: romm@ibanezyplaza.com

On-line version: <http://www.revistadeosteoporosisymetabolismomineral.com>

Editorial Committee

Teresita Bellido. PhD

Department of Medicine, Division of Endocrinology.
Indiana University School of Medicine. Indianapolis,
Indiana. Estados Unidos

Ernesto Canalis. MD, PhD

Director, Center for Skeletal Research. Professor of
Orthopedic Surgery and Medicine New England
Musculoskeletal Institute University of Connecticut Health
Center. Farmington, CT. Estados Unidos

Dr. Oswaldo Daniel Messina

Facultad de Medicina. Universidad de Buenos Aires.
Hospital Cosme Argerich. Buenos Aires. Argentina

Patricia Clark Peralta. MD, PhD

Facultad de Medicina, UNAM. Unidad Clínica
Epidemiológica. Hospital Infantil Federico Gómez. México
DF. México

Dr. Carlos Mautalen

Profesor Consultor Titular de la Facultad de Medicina.
Universidad de Buenos Aires. Director de "Mautalen, Salud
e Investigación". Buenos Aires. Argentina.

Lilian I Plotkin. PhD

Anatomy and Cell Biology. Indiana University School of
Medicine. Indianapolis, Indiana. Estados Unidos

Dr. Manuel Díaz Curiel

Universidad Autónoma de Madrid. Unidad de Metabolismo
Óseo. Hospital Fundación Jiménez Díaz. Instituto de
Investigación FJD. Fundación Hispana de Osteoporosis y
Metabolismo Mineral (FHOEMO). Madrid. España

Dr. Adolfo Díez Pérez

Universidad de Barcelona. Servicio de Medicina Interna.
Instituto Municipal de Investigación Médica. (IMIM).
Hospital del Mar. Barcelona. España

Dr. Francesc Xavier Nogués Solán

Universidad Autónoma de Barcelona. Unidad de
Investigación en Fisiopatología Ósea y Articular (URFOA).
Departamento de Medicina Interna, Parc de Salut Mar –
RETICEF. Barcelona. España

Dr. Manuel Sosa Henríquez (Director)

Universidad de Las Palmas de Gran Canaria. Grupo de
Investigación en Osteoporosis y Metabolismo Mineral.
Hospital Universitario Insular. Servicio de Medicina Interna.
Unidad Metabólica Ósea. Las Palmas de Gran Canaria.
España

Dra. María Jesús Gómez de Tejada Romero

(Redactora Jefe)
Universidad de Sevilla. Departamento de Medicina. Sevilla.
España

Committee of experts

Pilar Aguado Acín

María José Amérgo García

Abdón Arbelo Rodríguez

Miguel Arias Paciencia

Emilia Aznar Villacampa

Chesús Beltrán Audera

Pere Benito Ruiz

Santiago Benito Urbina

Miguel Bernard Pineda

Josep Blanch i Rubió

José Antonio Blázquez Cabrera

José Ramón Caeiro Rey

Javier Calvo Catalá

M^a Jesús Cancelo Hidalgo

Jorge Cannata Andía

Antonio Cano Sánchez

Cristina Carbonell Abella

Jordi Carbonell Abelló

Pedro Carpintero Benítez

Enrique Casado Burgos

Santos Castañeda Sanz

Fidencio Cons Molina

Sonia Dapia Robleda

Jesús Delgado Calle

Bernardino Díaz López

Casimira Domínguez Cabrera

Fernando Escobar Jiménez

José Filgueira Rubio

Jordi Fiter Areste

Juan José García Borrás

Juan Alberto García Vadillo

Eduardo Girona Quesada

Carlos Gómez Alonso

Milagros González Béjar

Jesús González Macías

Emilio González Reimers

Jenaro Graña Gil

Silvana di Gregorio

Daniel Grinberg Vaisman

Nuria Guañabens Gay

Roberto Güerri Fernández

Federico Hawkins Carranza

Diego Hernández Hernández

José Luis Hernández Hernández

Gabriel Herrero-Beaumont Cuenca

Esteban Jódar Gimeno

Pau Lluch Mezquida

José Andrés López-Herce Cid

M^a Luisa Mariñoso Barba

Guillermo Martínez Díaz-Guerra

María Elena Martínez Rodríguez

Leonardo Mellivobsky Saldier

Manuel Mesa Ramos

Pedro Mezquita Raya

Ana Monegal Brancos

Josefa Montoya García

María Jesús Moro Álvarez

Manuel Muñoz Torres

Laura Navarro Casado

Manuel Naves García

José Luis Neyro Bilbao

Xavier Nogués Solán

Joan Miquel Nolla Solé

José Antonio Olmos Martínez

Norberto Ortego Centeno

Santiago Palacios Gil-Antuñano

Esteban Pérez Alonso

Ramón Pérez Cano

José Luis Pérez Castrillón

Pilar Peris Bernal

Concepción de la Piedra Gordo

José Manuel Quesada Gómez

Enrique Raya Álvarez

Rebeca Reyes García

José Antonio Riancho Moral

Luis de Río Barquero

Luis Rodríguez Arboleya

Arancha Rodríguez de Gortázar

Alonso-Villalobos

Minerva Rodríguez García

Antonia Rodríguez Hernández

Manuel Rodríguez Pérez

Inmaculada Ros Villamajó

Rafael Sánchez Borrego

Oscar Torregrosa Suau

Armando Torres Ramírez

Antonio Torrijos Eslava

Carmen Valdés y Llorca

Carmen Valero Díaz de Lamadrid

Ana Weruaga Rey

METHODOLOGY AND DESIGN OF DATA

Pedro Saavedra Santana

José María Limiñana Cañal

Trabecular bone score and surgical treatment of primary hyperparathyroidism

Reyes García R^{1,2}, Muñoz-Torres M¹

1 Unidad de Metabolismo Óseo - Servicio de Endocrinología - Instituto de Investigación Biosanitaria de Granada - Hospital Universitario San Cecilio - Granada

2 Unidad de Endocrinología - Hospital General Universitario Rafael Méndez - Lorca - Murcia (Spain)

e-mail: rebecca.reyes.garcia@gmail.com

The surgical management of patients with primary hyperparathyroidism (HP) has resulted in several advances in recent decades which have improved the surgical management of this pathology, notable among which are the techniques of preoperative localisation, the use of minimally invasive techniques and the intraoperative determination of PTH. In spite of these advances, a number of controversies persist in terms of the surgical indications for patients with HP¹. The complementary tests necessary in the evaluation of the management of the patient with HP in order to define the degree of affectation and the indications for surgical treatment have also developed. In the latest recommendations of the Endocrine Society from 2014², in addition to carrying out a DXA they also recommend the evaluation of the presence of vertebral fractures by conventional radiology or other techniques, and the determination of the trabecular bone score (TBS) for a better definition of the trabecular affectation, which may not be correctly reflected in the densitometry. Furthermore, they recommend the determination of the presence of renal lithiasis by means of conventional X-rays or ultrasound, and the evaluation of the risk of lithiasis through the biochemical evaluation of urine. In respect of the classic criteria for surgery in patients with HP (less than 50 years of age, osteoporosis, history of fragility fracture, glomerular filtrate lower than 60 ml/min/1.72 m², or the presence of renal lithiasis), the recommendations of 2014 add the presence of vertebral fracture or lithiasis detected by respective imaging techniques, or the biochemical risk of lithiasis. In terms of the determination of the TBS, its relevance to the evaluation of the patient with HP is recognised, since it may mean a better estimation of the presence of an alteration in the level of trabecular bone in comparison with a DXA, and access to it may be less limited than other techniques such as HR-pQCT. However, no surgical criteria have been established as a function of the value of TBS due to its limited availability at the

current time, although it is recognised that this may change in the future.

The clinical case presented by Fernández-SanMillán et al.³ features a woman of 57 years of age in whom, in spite of not meeting the criteria for surgery according to the different recommendations, it was decided to perform a parathyroidectomy in response to the existence of a deterioration in trabecular bone structure determined by TBS and after locating an adenoma by gammagraphy. After surgery, an improvement in bone mineral density, and in markers for bone remodelling, were observed. The authors suggest the desirability of including, whenever possible, an estimation of the TBS in the evaluation of patients with HP, since if a deterioration of the bone microarchitecture is observed the indication of surgery could be recommended. In our opinion, this case raises an interesting question as to the need of a better evaluation of bone microarchitecture in patients with HP than we have made to date. The carrying out of a TBS, easier to do and more accessible compared with other techniques, could mean a significant advance in this matter. Although the current recommendations for surgery do not include alterations in TBS as a criterion for surgery, research in this field may change these criteria in the future.

Bibliography

1. Udelsman R, Åkerström G, Biagini C, Duh QY, Miccoli P, Niederle B, et al. The surgical management of asymptomatic primary hyperparathyroidism: proceedings of the Fourth International Workshop. *J Clin Endocrinol Metab* 2014;99:3595-606.
2. Silverberg SJ, Clarke BL, Peacock M, Bandeira F, Boutroy S, Cusano NE, et al. Current issues in the presentation of asymptomatic primary hyperparathyroidism: proceedings of the Fourth International Workshop. *J Clin Endocrinol Metab* 2014;99:3580-94.
3. Fernández-SanMillán D, Santana Borbones A, Pérez Alonso E, Santana JR, Hernández Hernández D, Sosa M. ¿Son válidos los criterios quirúrgicos actuales del hiperparatiroidismo primario asintomático? *Rev Osteoporos Metab Miner* 2015 7;1:15-9.

Briongos-Figuero LS, Abad-Manteca L, Cuadrado-Medina F, Pineda-Alonso M, Vega-Tejedor G, Pérez-Castrillón JL

Servicio de Medicina Interna - Hospital Universitario del Río Hortega - Valladolid

A986S polymorphism of calcium-sensing receptor and osteoporotic clinical fractures

Correspondence: Laisa Socorro Briongos-Figuero - Servicio de Medicina Interna - Hospital Universitario del Río Hortega - c/Dulzaina, 2 - 47012 Valladolid (Spain)
e-mail: laisadoc@hotmail.com

Date of receipt: 20/12/2014

Date of acceptance: 21/02/2015

Summary

Introduction: The relationship between osteoporosis and arterial hypertension has not been clearly established, with alterations in calcium metabolism having been reported in the latter which may explain their association. Our objective was to establish the relationship between the A986S polymorphism of the calcium-sensing receptor (CaSR) and the presence of osteoporotic clinical fractures in a group of patients with hypertension.

Material: Prospective observational cohort study in 71 patients with hypertension, from 2001 to June 2014. We obtained socio-demographic and clinical data, including osteoporotic clinical fractures. The CaSR polymorphism was analysed using molecular techniques. The data was analysed using SPSS 15.0 ($p < 0.5$)

Results: 43.77% of the patients were men and 56.3% women. Genotype AA was found in 67.6% of patients, genotype SS in 2.8% and genotype AS in 29.6%. Those with genotype AA did not have higher comorbidity (27% vs 26%, $p = 0.9$) or more pathological fractures (14.6% vs 21.7%, $p = 0.4$) than the others. In the subgroup of women, 11 osteoporotic clinical fractures were recorded, without there being any differences between those with the AA genotype and the others (28% vs 27%, $p = 0.9$).

Conclusions: We found no association between the A986S polymorphism and the presence of osteoporotic clinical fractures in our cohort.

Key words: osteoporosis, hypertension, calcium-sensing receptor, risk of fracture.

Introduction

Osteoporosis and arterial hypertension (AHT) are entities with a high prevalence in the general population, both clinically silent but becoming symptomatic when complications appear, such as fractures and cardiovascular diseases. Recent studies suggest that AHT is a risk factor for the appearance of pathological fractures^{1,2}. Thus, in patients with hypertension various alterations in the metabolism of calcium have been described, such as an increase in ionic calcium and an increase in PTH and calciuria, although only this last change has been associated with an increase in bone mass^{3,5}.

The calcium sensor receptor (CaSR) is coupled with G proteins and detects the extracellular concentrations of calcium. It is expressed in various cell types (kidney, bone – both in the osteoblasts and osteoclasts – and brain), although it is in the parathyroid cells where there is the highest density. Thus, CaSR plays an essential role in the homeostasis of calcium, regulating the calcium-parathyroid hormone (PTH)-vitamin D axis. On the other hand, CaSR controls the excretion and reabsorption of calcium in the ascending limb of the loop of Henle, acting on different transporters and also intervening in the regulation of arterial pressure^{6,9}. The polymorphism of codon 986 (A986) of CaSR is associated with an increase in blood levels of calcium and a decrease in calciuria, data antagonistic to those observed in arterial hypertension. Therefore, the objective of our study was to determine whether the presence of the S allele of the A986 polymorphism of CaSR might exert a protector effect on the appearance of clinical osteoporotic fractures in a group of patients with hypertension.

Material and methods

We designed a prospective observational study, initiated in 2001. A cohort of healthy people, with AHT as the only cardiovascular risk factor, was randomly selected with the aim of describing the incidence of complications over time. The patients were at stages I or II of systolic or diastolic hypertension, according to the criteria of the VI Meeting of the Joint National Committee (1997). The exclusion criteria were alcoholism, the presence of neoplasms, secondary hypertension, chronic renal insufficiency, hyper- or hypocalcaemia, diabetes, hyperparathyroidism and the use of drugs which may modify bone mineral density (BMD). The average duration of the hypertension was 7±8 years. A total of 71 patients were monitored until June 2014, taking at this point a cross section of our group to be studied. All the patients signed their informed consent and the study was approved by the clinical research committee of the Río Hortega University Hospital.

At the start of the study an analysis was made of calcium, phosphorus and magnesium using a Hitachi 917 autoanalyzer (Tokyo, Japan) and a densitometry of the lumbar spine (L2-L4) carried out with a Lunar densitometer (DEXA, Lunar Corporation, Madison, Wisconsin, US). Subsequently, socio-demographic

and clinical data was obtained from the digital clinical records, collecting data regarding treatments with different antihypertensives, the development of concomitant diseases and the incidence of pathological osteoporotic fractures (distal radial, vertebral and femoral neck) over time. The comorbidity was assessed using the Charlson Index (CI) in its original version of 19 items, as has been described in the literature¹⁰.

The analysis of the A986S polymorphism was performed using molecular biology techniques. The gene for CaSR is located in the 3q21.1 chromosome and can have inactivate or activate mutations. The A986S polymorphism is located in exon 7 and involves a change between alanine (A) and serine (S) in the intracellular C-terminal extreme of the receptor which generates a loss of function of the CaSR 9. To establish the genotype, a sample of blood anti-coagulated with EDTA was taken and the DNA extracted using the QIAmp Blood kit (Qiagen, Hilden, Germany). We designed the primers to amplify exon 7 (direct primer 5'CTTTGATGAGCCTCAGAAGAGC3' and inverse primer 5'ACAACCTCTTCAGGGTCCTCC3'), and the direct primer was modified by introducing a base change, thus creating a palindromic sequence which allowed us to recognise the nucleotide changes using restriction enzymes. The PCR was carried out using 25mM of each dNTP (Applied Biosystems, Branchburg, New Jersey, U.S.), 50 mM of CLK, 10 mM of Tris HCl (pH 8.3), 1.5 U of the DNA polymerase Amplitaq (Applied Biosystems, Foster City, California, U.S.), 2.5 mM of Cl₂Mg and 20 pmol of each primer, thus obtaining a total volume of 40 µl. The PCR was carried out in a Perkin Elmer 9600 thermal cycler (Norwalk, Connecticut, EE.UU.) with a temperature control system. The fragments were analysed by electrophoresis in an 8% acrylamide gel. Following the amplification the samples were added to the primers to create the specific restriction alleles for the BsaHI enzyme. The fragments obtained were digested by BsaHI (New England Biolabs, Stockholm, Sweden) and separated by electrophoresis in agarose gel. The presence of the BsaHI restriction fragment represents A, while its absence represents S, generating the genotypes AA, AS and SS.

The data were analysed with the statistical software package SPSS v15.0 (SPSS Inc[®]) with a level of significance for $p \leq 0.05$.

Results

Until the cross section of 2014 a total of 71 patients had been followed up, of whom 43.7% were men and 56.3% women, with an average age of 73.3±9 years, similar in both sexes (72.5±9 in the men and 74±9 in the women: $p=0.5$). 48% of our patients were more than 75 years of age. 17% of the patients died during the follow up period (all in the last two years).

At the baseline there were no differences between the two groups analysed (genotype AA and genotypes AS+SS). The rates of systolic (155±24 vs

154±20 mmHg, $p=0.841$) and diastolic (106±33 vs 93±11 mmHg, $p=0.569$) arterial pressure were similar. There were no differences in the levels of blood calcium (9.5±0.5 vs 9.8±0.4 mg/dl, $p=0.098$) or in calciuria (219±124 vs 275±175 mg/24h, $p=0.268$). The BMD in the lumbar spine also showed no differences between the two groups.

At the end of the period of follow up the average CI score was 1.7±2.7 (range 0-12), with high comorbidity in 22.65% of our patients and no comorbidity, according to CI, in 73.2% of them. In terms of the appearance of other concomitant diseases, 18.3% of the individuals were diabetic, 32.4% had cardiovascular risk factors other than AHT, 14% developed ischemic cardiomyopathy, 12.7% cerebrovascular disease and the same percentage showed some degree of cognitive deterioration. On the other hand, 17% had at least one pathological osteoporotic fracture (8.5% vertebral, 5.3% femoral neck, 2.8% distal radial).

The genotype AA was found in 67.6%, SS in 2.8% and AS in 29.6% of the patients, with an allelic frequency A of 0.82 and S of 0.18, being in Hardy-Weinberg equilibrium ($\chi^2=0.03$; $p=0.8696 >0.05$). The individuals with genotype AA, compared with the other genotypes (AS+SS), did not have more cardiovascular risk factors (29.2% vs 39%, $p=0.4$), cardiovascular disease (12.5% vs 17.4%, $p=0.5$), presence of comorbidity according to CI (27% vs 26%, $p=0.9$), higher mortality (18.8% vs 13%, $p=0.5$) or a greater number of pathological fractures overall (14.6% vs 21.7%, $p=0.4$) nor specific fractures (vertebral 6.3% vs 13%, $p=0.3$; femoral neck 6.3% vs 4.3%, $p=0.6$; distal radial 2.1% vs 4.3%, $p=0.5$).

The average age of the women at the start of the study was 59±9.9 years, all postmenopausal, with a body mass index of 28±4. The average systolic arterial pressure was 155±22 mmHg and the diastolic was 93±10 mmHg. In the subgroup of women, those with the AA genotype had more pathological fractures, especially in the femoral neck, with no statistical association (12% vs 6.7%, $p=0.5$). The characteristics of the groups as a function of their sex and genotype is shown in Table 1.

Discussion

Calcium homeostasis plays a fundamental role in bone remodelling, and the alterations in the mechanisms involved in their regulation contribute to the development of pathology in bone metabolism¹¹. The CaSR gene is a candidate gene for the determination of susceptibility to osteoporosis in AHT, the A986S locus of CaSR having been related to the maintenance of the concentration of extracellular ionic calcium within a narrow range¹², and with calciuria. The higher degree of elimination of calcium in patients with hypertension has been related with a decreased in BMD and, as a consequence, with a possible increase in the risk of fracture. On the other hand, AHT has been associated with raised levels of PTH, which accelerates bone remodelling, affecting both bone quality and mass¹³.

Contrary to our expectations and consistent with a number of studies^{7,14}, we found no direct relationship between the genotypes of the A986S polymorphism and the incidence of pathological fractures, and no increase in the risk of pathological fractures in those patients who were carriers of allele S. Our data agree with a study previously published by our research group in which, in a population of women with hypertension, no differences were found in calcaemia, calciuria, levels of PTHi or BMD in the lumbar spine when categorised according to genotype AA or genotype AS+SS¹⁵.

There are not many works which evaluate the influence of the A986S polymorphism on the risk of fractures. On the one hand, various studies carried out in European Caucasian populations found an association only in the young population⁶, but not in postmenopausal women or in those with hypertension^{11,15}. However, there are contradictory data in the literature. Thus, März et al.¹⁶, did establish an association between the S allele and cardiovascular risk factors. Cetani et al.¹¹, investigating the effect of the polymorphism on fragility fractures in a group of 164 postmenopausal women, found no differences. Bollerslev et al.¹⁷ analysed the association between polymorphism, bone mass and fractures in a cohort of 1,252 postmenopausal women without finding any relationship. This possible relationship has been analysed in other populations. Thus, Gianini et al.¹⁸, studied 87 women subject to renal transplant and with persistent secondary hyperparathyroidism and found negative results similar to our group. Recently, an Italian group studied risk factors for vertebral fractures in a population with primary hyperparathyroidism. They studied 266 individuals (229 women and 37 men) with a genotype distribution similar to our group. They found that the presence of the S allele (evaluated as the AS+SS genotype) is associated with an increase in the risk of vertebral fractures with an odds ratio of 1.8 (95% CI: 1.1-2.9, $p=0.05$) after adjusting for age, sex, BMI, BMD and blood calcium. This population is different from ours, the key factor being the role of PTH regulated by the calcium sensor receptor¹⁹.

The main limitation of our study is the sample size and the non-recording of morphometric fractures. Its strength comes from the homogeneity of the population studied, the long period of follow up and the use of an objective variable, as are clinical fractures.

In conclusion, the association between the genotypes of the A986S polymorphism of CaSR and the incidence of pathological fractures is difficult to establish and the different studies yield contradictory data, contributing to the increasing the confusion in this field. In our study we found no association between the A986S polymorphism of CaSR and clinical osteoporotic fractures, either in the general cohort or in the subgroup of women, although the etiopathogeny of osteoporosis in this population with hypertension can be determined by levels of blood calcium, hypercalciuria and the possibility of secondary hyperparathyroidism.

Table 1. Characteristics of women and men studied as a function of genotype

Characteristics	Women			Men			
	Genotype AA N=25 (%)	Genotype SS+AS N=15 (%)	Value P	Genotype AA N=23 (%)	Genotype SS+AS N=8 (%)	Value P	
Age (years), mean \pm SD	75 \pm 10	71 \pm 9	ns	72 \pm 10	72 \pm 9	ns	
Age >75 years	16 (64)	5 (33)	ns	9 (39)	4 (50)	ns	
Score CI, mean \pm SD	1.3 \pm 2	1.8 \pm 2	ns	2.4 \pm 3	1.2 \pm 2	ns	
CI group	without comorbidity	22 (88)	11 (73)	ns	13 (56)	6 (75)	ns
	with comorbidity	3 (12)	4 (27)	ns	10 (44)	2 (25)	ns
(Global) mortality	3 (12)	1 (6.7)	ns	6 (26)	2 (25)	ns	
BMD (gHA/cm ²)	1.061 \pm 0.16	1.040 \pm 0.15	ns	1.136 \pm 0.15	1.148 \pm 0.16	ns	
Pathological fracture	7 (28)	4 (26.7)	ns	0 (0)	1 (12.5%)	ns	

SD: standard deviation; CI: Charlson index; ns: not significant; BMD: bone mineral density.

Bibliography

- Yang S, Nguyen ND, Center JR, Eisman JA, Nguyen TV. Association between hypertension and fragility fracture: a longitudinal study. *Osteoporos Int* 2014;25:97-103.
- Pérez-Castrillón JL, Martín-Escudero JC, Álvarez Manzanares P, Cortes Sancho R, Iglesias Zamora S, García Alonso M. Hypertension as a risk factor for hip fracture. *Am J Hypertens* 2005;18:146-7.
- Gadallah M, Massry SG, Bigazzi R, Horst RL, Eggena P, Campese VM. Intestinal absorption of calcium and calcium metabolism in patients with essential hypertension and normal renal function. *Am J Hypertens* 1991;4:404-9.
- Pérez-Castrillón JL, Justo I, Silva J, Sanz A, Igea R, Escudero P, et al. Bone mass and bone modelling markers in hypertensive postmenopausal women. *J Hum Hypertens* 2003;17:107-10.
- Tsuda K, Nishio I, Masuyama Y. Bone mineral density in women with essential hypertension. *Am J Hypertens* 2001;14:704-7.
- Lorentzon M, Lorentzon R, Lerner UH, Nordstrom P. Calcium sensing receptor gene polymorphism, circulating calcium concentrations and bone mineral density in healthy adolescent girls. *Eur J Endocrinol* 2001;144:257-61.
- Pratt JH, Ambrosius WT, Wagner MA, Maharry K. Molecular variations in the calcium-sensing receptor in relation to sodium balance and presence of hypertension in blacks and whites. *Am J Hypertens* 2000;13:654-8.
- Brown EM, Gamba G, Riccardi D, Lombardi M, Butters R, Kifor O, et al. Cloning and characterization of an extracellular Ca(2+)-sensing receptor from bovine parathyroid. *Nature* 1993;366:575-80.
- Yun FH, Wong BY, Chase M, Shuen AY, Canaff L, Thongthai K, et al. Genetic variation at the calcium-sensing receptor (CASR) locus: implications for clinical molecular diagnostics. *Clin Biochem* 2007;40:551-61.
- Charlson ME, Pompei P, Ales KL, MacKenzie CR. A new method of classifying prognostic comorbidity in longitudinal studies: development and validation. *J Chronic Dis* 1987;40:373-83.
- Cetani F, Pardi E, Borsari S, Vignali E, Dipollina G, Braga V, et al. Calcium-sensing receptor gene polymorphism is not associated with bone mineral density in Italian postmenopausal women. *Eur J Endocrinol* 2003;148:603-7.
- Cole DE, Peltekova VD, Rubin LA, Hawker GA, Vieth R, Liew CC, et al. A986S polymorphism of the calcium-sensing receptor and circulating calcium concentrations. *Lancet* 1999;353:112-5.
- Cappuccio FP, Kalaitzidis R, Dunelclift S, Eastwood JB. Unravelling the links between calcium excretion, salt intake, hypertension, kidney stones and bone metabolism. *J Nephrol* 2000;13:169-77.
- Blázquez JA, Navarro L, Andrés C, Ontañón J, Navarro A, del Pino J. Relación entre el polimorfismo A986S del CaSR y presión arterial en mujeres postmenopáusicas recientes. *Rev Esp Enf Metab Óseas* 2008;17:137.
- Pérez-Castrillón JL, Sanz A, Silva J, Justo I, Velasco E, Dueñas A. Calcium-sensing receptor gene A986S polymorphism and bone mass in hypertensive women. *Arch Med Res* 2006;37:607-11.
- März W, Seelhorst U, Wellnitz B, Tiran B, Obermayer-Pietsch B, Renner W, et al. Alanine to serine polymorphism at position 986 of the calcium-sensing receptor associated with coronary heart disease, myocardial infarction, all-cause, and cardiovascular mortality. *J Clin Endocrinol Metab* 2007;92:2363-9.
- Bollerslev J, Wilson SG, Dick IM, Devine A, Dhaliwal SS, Prince RL. Calcium-sensing receptor gene polymorphism A986S does not predict serum calcium level, bone mineral density, calcaneal ultrasound indices, or fracture rate in a large cohort of elderly women. *Calcif Tissue Int* 2004;74:12-7.
- Giannini S, Sella S, Silva Netto F, Cattelan C, Dalle Carbonare L, Lazzarin R, et al. Persistent secondary hyperparathyroidism and vertebral fractures in kidney transplantation: role of calcium-sensing receptor poly-

- morphisms and vitamin D deficiency. *J Bone Miner Res* 2010;25:841-8.
19. Eller-Vainicher C, Battista C, Guarnieri V, Muscarella S, Palmieri S, Salcuni AS, et al. Factors associated with vertebral fracture risk in patients with primary hyperparathyroidism. *Eur J Endocrinol* 2014;171:399-406.

Suárez Bordón S¹, González González Y², Santana Borbones M³, Herrera Henríquez J³, Hernández Hernández D⁴, Sosa Henríquez M^{1,4}

1 Instituto Universitario de Investigaciones Biomédicas y Sanitarias (UIBS) Grupo de Investigación en Osteoporosis y Metabolismo Mineral - Universidad de Las Palmas de Gran Canaria - Las Palmas de Gran Canaria

2 Servicio de Radiología - Hospital Universitario Insular de Gran Canaria

3 Servicio de Medicina Nuclear - Hospital Universitario Insular de Gran Canaria

4 Unidad Metabólica Ósea (Servicio de Medicina Interna) - Hospital Universitario Insular de Gran Canaria

Melorheostosis: presentation of a clinical case

Correspondence: Saray Suárez Bordón - c/Goya, 50 - 35110 Vecindario - Las Palmas (Spain)
e-mail: Saray.sbb@gmail.com

Date of receipt: 05/03/2015

Date of acceptance: 20/03/2015

Summary

Melorheostosis is a form of hyperostosis which affects both bone and the adjacent soft tissues. Its incidence is variable, although it is higher in the second and third decades of life due to the slowly progressive nature of the disease. It generally presents with pain which may cause significant functional limitation. We may be assisted in its diagnosis by its characteristic radiological image which resembles “wax melting down the side of a candle”. A case of melorheostosis is presented with clinical findings and radiological characteristics. The patient had previously been diagnosed with Paget’s disease of bone, so we proposed a differential diagnosis of this pathology.

Key words: *melorheostosis, Paget’s disease of bone, differential diagnosis.*

Introduction

The term melorheostosis is derived from the Greek suffixes melos (limbs), rhein (fluid/flow) and osteon (bone). This disease is also known as hyperostotic osteopathy or Leri and Joanny disease¹ (the first to describe the disease in 1922). It is a rare form of hyperostosis which affects both the bone tissue and the adjacent soft tissues. Its incidence is 0.9 cases per million population. In 50% of cases it is diagnosed before the age of 20, without predilection regarding the sex of the person². It consists of a benign process without associated mortality, but which generates functional limitations. Its etiology and etiopathogeny are unknown. Genetic alterations associated with the disease have recently been described³. Any bone may be compromised, with the lower limbs being the most affected⁴. The diagnosis is usually carried out through diagnostic imaging techniques, notable among which is simple radiography⁵. With this we may observe an image which resembles "wax dripping down the side of a candle", a sign which gives us a secure diagnosis in most cases^{6,7}. The treatment is mainly symptomatic, and only occasionally requires recourse to surgery.

Clinical Case

A male patient 36 years of age referred in 2009 for a check up to his bone metabolism unit (BMU) and diagnosed in a private bone disease clinic with monostotic Paget's disease of bone in the left radius. The patient brought with him a biopsy and gammagraphy carried out in 2007. He was treated with risedronate at a dose used for osteoporosis. On confirmation of a good level of P1NP (amino-terminal propeptide of procollagen type 1), the same year, 2009, the risedronate was withdrawn. From then, and up to November 2014 he was periodically checked for the blood level of markers for bone remodelling, with a new cycle of risedronate at a low dose indicated for him for a few months until the levels increased.

Also in this period a gammagraphy was performed without there being seen significant alterations from the earlier measurements. On administering the treatment the patient's local pain improved, but in November 2014 he spontaneously attended the clinic with his arm in a sling saying that two days before he had suffered an accidental fall and was experiencing intense pain in the left carpal region. In a physical examination a haematoma was found in the back of the hand and the distal third of the forearm, oedema, effacement of the tendonous sulci of the back of the hand, functional weakness in the wrist and a local increase in temperature. With the clinical suspicion of fracture, he was referred from the bone metabolism unit to the accident and emergency department where X-rays were carried out. He was discharged with the diagnosis of contusion there being no evidence of fracture, but a large hyperostotic lesion was observed (Figure 1) in the simple X-rays, for which reason the patient again attended the BMU. In spite of a fracture not being seen

in the X-rays, but there being clinical evidence, a computerised axial tomography (CAT) was requested urgently, and a nuclear magnetic resonance (NMR) scan for a deferred study of the hyperostotic lesion. In the CAT scan a fracture was seen in the hamate and trapezoid bones. The limb was immobilised with a posterior ferrule. Once the traumatological emergency was resolved, in the following days the radiological lesion of the radius was evaluated with the so called sign of "dripping melted wax" being identified. Given the possibility of melorheostosis, this option was suggested to the radiology and nuclear medicine service for their consideration. In the end, it was accepted as an alternative diagnosis to Paget's disease of bone, their gammagraphy being indistinguishable. Once the new diagnosis of melorheostosis was confirmed and agreed we resumed the anamnesis, which, notably, recounted a fall at the age of 14 when practicing sport. The patient said that that he had suffered intense pain in the radius, but that he did not attend any health centre and hid it from his parents, having had since then some deformity. The pain subsided some weeks after the fall. We deduced that the patient had fractured his radius, and by neither immobilising nor reducing the fracture he was left with this deformity which can be seen in Figure 1, but which bears no direct relation with hyperostosis. Besides the striking central image, there are other areas of hyperostosis in the interior of the distal end of the radius, and in the proximal third.

Discussion

The exposition and development of the case presented invites a number of points of reflection. Firstly: should all diagnoses be called into question even if they are properly documented? In the case we are dealing with "everything had already been done": the X-rays, although we never saw them, only the reports; also the pathological anatomy report following a biopsy, and the report of a gammagraphy, which could be viewed, having been stored in the hospital in the patient's clinical record.

The second point of reflection is related to the trauma and raises the issue of the validity of clinical data as against complementary examination. Although the carpal fractures were not observed in the simple X-ray, the clinical evidence and our insistence led us to request an urgent CAT scan.

With regard to melorheostosis, we present this case because of the infrequency of the disease itself and the doubts which may be raised when trying to make a correct differential diagnosis with other pathologies.

Generally, when it affects a long bone, we can in practice obtain a diagnosis using a simple X-ray⁵ with the characteristic image of "melted wax flowing down the side of a candle". However, on many occasions we need a bone biopsy or bone gammagraphy to discount pathologies which affect bone metabolism. The initial diagnosis was not totally uncertain given that in Paget's disease,

in response to bone resorption, there is an increase in bone formation, resulting in an increase in the thickness of some trabeculae and an irregular hypertrophy of the trabecular bone⁷. As a consequence, the bone marrow is infiltrated with an excess of fibrous connective tissue and of blood vessels which lead to hypervascularisation, findings which are compatible with melorheostosis where the cortical hyperostosis causes thickening and trabecular bone and vascular increase. It should be borne in mind that in melorheostosis the microscopic appearance is not always the same, since it depends on the point in time at which the sample is obtained, similarly to Paget's disease of bone. However, in order to carry out a differential diagnosis with the latter condition it is noteworthy that in melorheostosis, as well as presenting intramembranous ossification with the increase in the activity of the osteoblasts, there are certain consistent alterations such as an irregular diameter of the Haversian canals and an irregular lamellar pattern in the trabecular area⁸, anatomopathological data which facilitate a definitive diagnosis. In relation to the gammagraphy, in Paget's disease there is an increased radiopharmacological capture which may give us images similar to melorheostosis⁹. This leads one to suppose that in melorheostosis there is an increase in bone metabolism which translates into an increased trace^{10, 11} due to the presence of immature collagen and changes in vascular permeability. In addition, the gammagraphy¹² also allows the differential diagnosis of melorheostosis with other diseases which develop with hyperostotic lesions such as osteopoikilosis and striated osteopathy^{13,14}, two conditions in which there is no gammagraphy capture. Lastly, the lightest forms of melorheostosis present more difficulties in differential diagnosis with periosteal osteosarcoma or myositis ossificans¹⁵.

In the case we present, a credible documented prior diagnosis, a conservative attitude on our part in preventing exposure to ionising radiation and the superimposition of the data of two different diseases, meant that for several years the patient had an erroneous diagnosis, until a fortuitous trauma and a new X-ray invited a re-evaluation of the case.

Bibliography

1. Lery A, Joanny J. Une affection non décrite des os: hyperostose «en coulée» sur toute la longueur d'un membre ou «melorhéostose». Bull Mem Soc Med Hôp Paris 1992;46:1141-5.
2. McDermott M, Branstetter 4th BF, Seethala RR. Craniofacial melorheostosis. J Comput Assist Tomogr 2008;32:825-7.
3. Hellemans J, Preobrazhenska O, Willaert A, Debeer P, Verdonk PC, Costa T, et al. Loss-of-function mutations in LEMD3 result in osteopoikilosis. Buschke-Ollendorff syndrome and melorheostosis. Nat Genet 2004;36:1213-8.
4. Yildirim C, Ozyürek S, Çiçek EI, Kuskucu M. Melorheostosis in the upper extremity. Orthopedics 2009;32. Disponible en: <http://www.orthosupersite.com/view.asp?rID=38064>, consultado el 3 de marzo.
5. Brown RR, Steiner GC, Lehman WB. Melorheostosis: case report with radiologic-pathologic correlation. Skeletal Radiol 2000;29:548-52.
6. Nuno C, Heili S, Alonso J, Alcalde M, López P, Villacastin B, Calvo E, Mazarbeitia F. Melorreostosis: presentación de un caso y revisión de la literatura. Rev Esp Enf Metab Óseas 2001;10:50-5.
7. Salman-Monte TK, Rotés-Sala D, Blanch-Rubió J, Bittermann V, Carbonell Abelló J. Melorreostosis: presentación de un caso y revisión de la literatura Reumatol Clin 2011;7:346-8.

Figure 1. Injury hiperostótica melorheostosis, radiological sign of "melted wax". Angulation of the secondary radio an old fracture of unknown origin at the age of 14 years

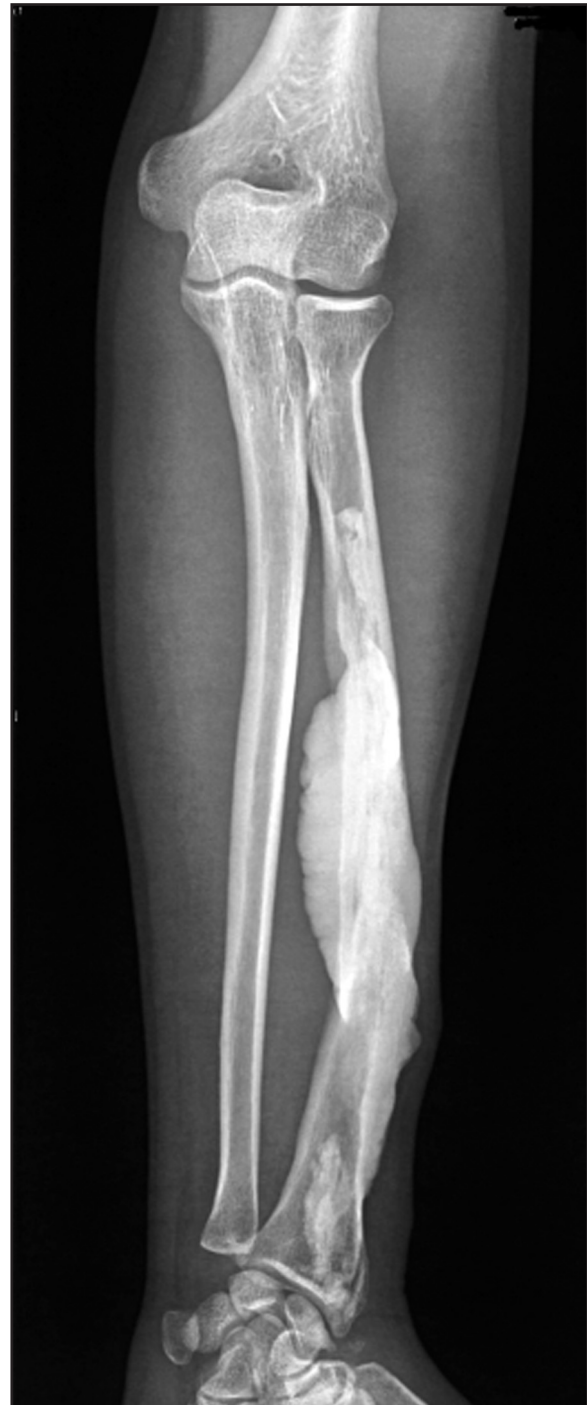
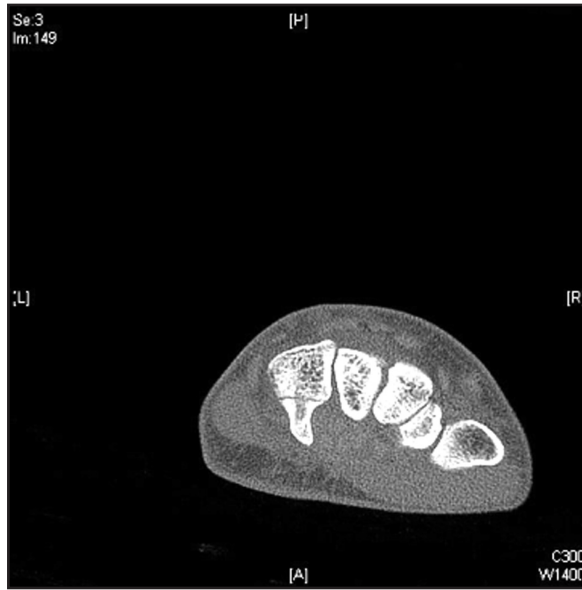
Figure 2. Clearly the hamate fracture, left wrist, after trauma



8. Meunier PJ, Coindra J, Edouard C, Arlot ME. Bone histomorphometry in Paget's disease: Quantitative and dynamic analysis of pagetic and non-pagetic bone tissue. *Arthritis Rheum* 1980;23:1095-103.
9. Rozencwaig R, Wilson MR, McFarland GB. Melorheostosis. *Am J Orthop* 1997;26:83-9.
10. Judkiewicz AM, Murphey MD, Resnik CS, Newberg AH, Temple HT, Smith WS. Advanced imaging of melorheostosis with emphasis on MRI. *Skeletal Radiol* 2001;30:447-53.
11. Kloos RT, Shreve P, Fig L. Melorheostosis bone scintigraphy and F-18 fluorodeoxyglucose positron emission tomography. *Clin Nucl Med* 1996;21:805-6.
12. Spieth ME, Greenspan A, Forrester DM. Radionuclide imaging in forme fruste of melorheostosis. *Clin Nucl Med* 1994;19:512-5.
13. Pascaud-Ged E, Rihouet J, Pascaud JL. Melorheostosis, osteopoikilosis and linear scleroderma. *Ann Radiol (Paris)* 1981;24:643-6.
14. Whyte MP, Murphy WA, Fallon MD. Mixed-sclerosing-bone-dystrophy: report of a case and review of the literature. *Skeletal Radiol* 1981;6:95-102.
15. Faruqi T, Dhawan N, Bahl J, Gupta V, Vohra S, Tu K, Abdelmagid SM. Molecular, phenotypic aspects and therapeutic horizons of rare genetic bone disorders. *BioMed Res Int* 2014, 2014:670842. doi: 10.1155/2014/670842. Epub 2014 Oct 22.

Fernández-SanMillán D^{1,2}, Santana Borbones A^{1,3}, Pérez Alonso E^{1,2}, Santana JR², Hernández Hernández D^{1,4}, Sosa Henríquez M^{1,4}

1 Universidad de Las Palmas de Gran Canaria - Instituto Universitario de Investigaciones Biomédicas y Sanitarias (IUIBS) - Las Palmas de Gran Canaria

2 Hospital Universitario Insular - Servicio de Cirugía General y Aparato Digestivo - Las Palmas de Gran Canaria

3 Hospital Universitario Insular - Servicio de Medicina Nuclear - Las Palmas de Gran Canaria

4 Hospital Universitario Insular - Unidad Metabólica Ósea - Las Palmas de Gran Canaria

Are the current surgical criteria for asymptomatic primary hyperparathyroidism valid?

Correspondence: David Fernández-SanMillán - c/Profesora Concha Romero, 11 - 35250 Ingenio - Las Palmas (Spain)
e-mail: san_millan@yahoo.es

Date of receipt: 09/03/2015

Date of acceptance: 24/03/2015

Summary

HPTP is a very frequent pathology which often develops asymptotically. Surgical intervention being the only curative treatment for this disease there are some criteria for the indication of surgery, but these do not always fit the reality of the patient since they are based on clinical complications (osteoporosis, renal insufficiency, urolithiasis, fragility fractures).

We present the clinical case of a patient who did not meet any of the requirements for having surgical intervention according to the position documents, and who was operated on after the existence was shown of a deterioration of the trabecular bone structure, determined by the TBS (trabecular bone score) technique, and located in the adenoma using gammagraphy. The possible use of these techniques, not seen in the position documents, to complement the decision regarding surgery, is discussed.

Key words: *primary hyperparathyroidism, diagnosis, consensus, surgery, densitometry, TBS.*

Introduction

Primary hyperparathyroidism (PHPT) is one of the most frequent endocrinopathies, which affects, above all, women over 50 years of age¹⁻⁴. Nowadays, in most of these cases the diagnosis occurs casually, incidental to an analytical study, and the patient is often completely asymptomatic.

In the long term, PHPT may produce a series of complications, such as chronic renal insufficiency, urolithiasis, osteoporosis, fragility fractures and fibrocystic osteopathy¹⁻⁶. On over 90% of occasions PHPT is due to an adenoma and surgery is the only curative treatment^{3,4}. It being preferable to avoid these complications before they occur, there is a discussion as to when it is advisable to intervene surgically in a patient who is clinically asymptomatic. To throw light on this matter a number of position documents have been published⁵⁻¹⁰, without there being unanimous agreement^{2-4,10,11}. Techniques such as bone densitometry help to establish the existence of osteoporosis as a complication^{3,6}, and recently a new technique has been introduced, the trabecular bone score (TBS), which is intended to evaluate the integrity and connectivity of the trabeculae of the vertebrae¹²⁻¹⁵, with some studies having been published which show the early effects of PHPT¹⁴⁻¹⁶.

While intervention criteria are a widely used tool when taking a therapeutic decision, on occasion the patient may benefit from surgery in spite of their not strictly meeting these criteria. We present the case of a patient affected by PHPT, in whom surgery was not indicated by any of the position documents, but in whom there was a deterioration in bone evaluated by TBS, and in whom the adenoma was located by gamma-graphy, with a surgical intervention and a notable clinical and densitometric improvement having been confirmed a year later.

Presentation of Case

A female patient, 57 years of age in 2013, who was referred to our unit for an examination for asymptomatic hypercalcaemia.

It is worth noting from her personal history that the patient was diagnosed with diabetes mellitus type 2 (controlled through diet and oral anti-diabetics), hypercholesterolemia, arterial hypertension and morbid obesity (BMI = 50.5 kg/m²). For these conditions she received statins, metformin and an angiotensin converting enzyme inhibitors (ACEi) She was clinically asymptomatic and the hypercalcaemia was detected by her primary care doctor in the context of a metabolic check-up due to her previous pathologies. She had the menopause at 48 years of age but did not receive hormone replacement therapy following this. She had not suffered fractures.

The existence of asymptomatic primary hyperparathyroidism PHPT having been confirmed due to the presence of high calcaemia, corrected with total proteins, high blood PTH, and having excluded other causes of hypercalcaemia, the patient was submitted for surgery, a right triportal video-

thoracoscope being carried out, the existence of an adenoma being confirmed intra-operationally, which was then resected.

Table 1 gives the analytical data for the patient before, and one year after, surgery, along with the reference values for our hospital.

Table 2 shows the densitometric data, including the TBS before, and one year after, the surgical intervention. The densitometry was carried out using a Hologic® Discovery 4500 densitometer, and the estimation of the TBS was made using the program provided by TBS insights of the Medimaps Group with the same densitometer.

In Table 3 are shown the indication criteria for surgery in asymptomatic primary hyperparathyroidism (PHPT) since 1990 until the last update in 2013, along with the clinical data of the patient.

In Figure 1, the MIBI-technetium 99 gamma-graphy of the parathyroids shows the presence of a focus of high activity in the central thoracic area and situated retrosternally, which suggests the existence of a parathyroid adenoma in the mediastinum. Lastly, in Figure 2, the development is shown of both the DXA and the TBS in the lumbar spine one year after surgery.

Discussion

PHPT is a very common pathology, whose incidence has been estimated as 121 cases/100,000 of the population per year¹, and which is increasing. Primary hyperparathyroidism is being diagnosed increasing early due to the testing for calcaemia in routine analyses, such as occurred in the case we present. Often the patient is completely asymptomatic, and for us this raises the question as to the possible benefit the patient might obtain from surgical intervention²⁻⁴.

From 1990 up until 2014 some criteria have been published by the "Workshop on surgical indications in asymptomatic primary hyperparathyroidism"^{7,5-10}. The clinical and analytical data listed in these are very similar, varying only in some details, such as the change in the densitometric evaluation from the Z-score included in the 1990 criteria⁵ to the T-score from 2002^{6,9}, and the inclusion of fragility fractures from 2008^{6,7}. The last consensus in 2014 included the risk of urolithiasis, either analytical or biochemical, as well as the presence of nephrolithiasis or nephrocalcinosis⁶. On the other hand, age, below 50 years, and hypercalcaemia of 1 mg above the upper limit, have remained unchanged in all the documents. However, some authors suggest that other factors such as baseline PTH, could have greater predictive power of the development of PHPT¹¹.

Our patient did not comply with any of the published criteria for surgical intervention. Nevertheless, we offered her the possibility of surgery for four reasons: a) there was a deterioration in bone microarchitecture, estimated by TBS in the lumbar spine, despite the DXA being normal (Figure 2); b) the adenoma was located in the mediastinum as imaging tests carried out of the parathyroids using MIBI-Technetium⁹⁹, SPECT and

Table 1. Biochemical values obtained in the patient before and after surgery, with the reference values in our Hospital

	20/07/2013	08/07/2014	Reference values
Urea, mg/dl	47	34	10-50
Creatinine, mg/dl	0.7	0.7	0.6-1
GFR MDRD4, ml/m/1,73 m ²	>60	>60	>60
Total calcium, mg/dl	10.9	9.7	8.5-10.5
Corrected calcium, mg/dl	10.9	9.6	8.5-10.5
Phosphorus, mg/dl	3.5	3.3	2.5-4.9
Total protein, g/l	7.2	7.4	6.4-8.4
PTH, pg/ml	117	46.9	15-88
P1NP, ng/ml	36.2	42.2	<37.1
Beta-crosslap, ng/ml	0.52	0.35	0-0.57
Osteocalcin, ng/ml	24.5	14.6	11-43
TRAP, UI/l	2.5	3.2	0-3.3
25 (OH) vitamin D, ng/ml	39.9	26.1	30-80
Calciuria, mg/24h	360	NR	<250

GFR MDRD4: glomerular filtration rate by MDRD4; P1NP: amino-terminal propeptide of procollagen type 1; TRAP: Tartrate-resistant acid phosphatase; NR: not done.

Table 2. Densitometric values of patient before and after surgery. T-score and Z-score obtained from normal values in the Spanish population

	24/07/13	28/03/14	% Annual change
L2-L4 (g/cm ²)	1.109	1.162	4.8*
T-score	0.7	1.2	4.8*
Z-score	2.3	2.9	4.8*
TBS L2-L4 (g/cm ²)	1.145	1.272	16.5*
Total hip (g/cm ²)	1.135	1.098	3.5
T-score	1.6	1.3	3.5
Z-score	2.4	2.1	3.5
Femoral neck (g/cm ²)	0.762	0.789	3.5
T-score	-0.7	-0.5	3.5
Z-score	0.5	0.8	3.5

* Statistically significant change (p<0.05).

Tomo-SPECT suggested (Figure 1); c) having no doubts about the clinical diagnosis or its location it seemed to us improper to wait to see if any complications might appear before intervening; and, d) it is the only curative treatment of PHPT.

A year after having had surgery the patient was clinically asymptomatic. The calcaemia had normalised, the bone mineral density (BMD) had increased in the lumbar spine by almost 5% and the TBS had improved by 16.5%. Therefore, we

Table 3. Criteria for surgical indication of PHPT from 1990-2013

Year (quote)	1990 (2)	2002 (5)	2008 (4)	2013 (3)
Age	<50	<50	<50	<50
Calcemia	>1 mg/dl the upper limit	>1 mg/dl the upper limit	>1 mg/dl the upper limit	>1 mg/dl the upper limit
Clearing creatinine/GF	eGFR reduction >30%	eGFR reduction >30%	eGFR <60 ml/min	eGFR <60 ml/min
Osteoporosis densitometric and/or fracture brittle	Z-Score <-2.0 (specific site)	T-Score <-2.5 (anywhere)	T-Score <-2.5 (anywhere), and/or fracture previous fragility	T-Score <-2.5 (lumbar, hip, femoral neck, distal radius 1/3) and/or diagnosed by image vertebral fracture*
Calciuria 24 hours	>400 mg/dl	>400 mg/dl	>400 mg/dl	>400 mg/dl
Others				Risk of stones or biochemical analy- tical or nephroli- thiasis or nephro- calcinosis presence

GF: glomerular filtration; eGFR: estimated glomerular filtration rate.

* Includes lateral radiograph dorso-lumbar spine, magnetic resonance imaging or computed tomography.

consider that in spite of the patient not meeting the surgical intervention criteria the decision was correct. This leads us to suggest the need to include in the indications for surgery for asymptomatic HPT, on the one hand the evaluation of the TBS, and on the other, the carrying out of a gamma-graphy of the parathyroids, at least as an optional test. Although the measurement of the TBS is a relatively recent technique^{12,13} a number of studies have described its alteration in PHPT^{5,14-16}. We should take into account the fact that the values of TBS may have been affected by the morbid obe-

sity from which our patient suffered, as has been mentioned earlier¹³.

In conclusion, and from the results obtained in this patient, we suggest the need to include, whenever possible, both an estimation of the TBS, as well as a MIBI-Technetium⁹⁹ gammagraphy of the parathyroids, since in the case of a deterioration in bone architecture being observed, or of locating, unequivocally, an adenoma, a surgical indication could be advised. This coincides with the recommendations made by the American Association for Clinical Endocrinology and the American Association of Endocrine Surgery, both of which organisations indicate that "it is unacceptable to have to live with a chronic disease, which in the long term may cause health problems, a disease which could be cured by surgery in the majority of cases"¹⁷.

Conflict of interest: The first author, in the name of the other co-authors, declares that there are no conflicts of interest.

Bibliography

- Griebeler ML, Kearns AE, Ryu E, Hathcock MA, Melton LJ 3rd, Wermers RA. Secular trends in the incidence of primary hyperparathyroidism over five decades (1965-2010). *Bone* 2014;73C:1-7.
- Bollerslev J, Jansson S, Mollerup CL, Nordenstrom J, Lundgren E, Topping O, et al. Medical observation, compared with

Figure 1. MIBI scintigraphy Tecnetio⁹⁹ parathyroid showing the existence of a mediastinal adenoma location

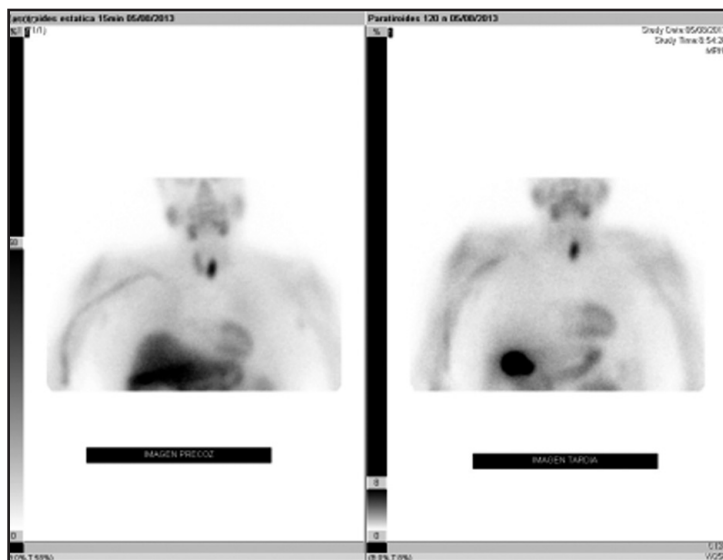
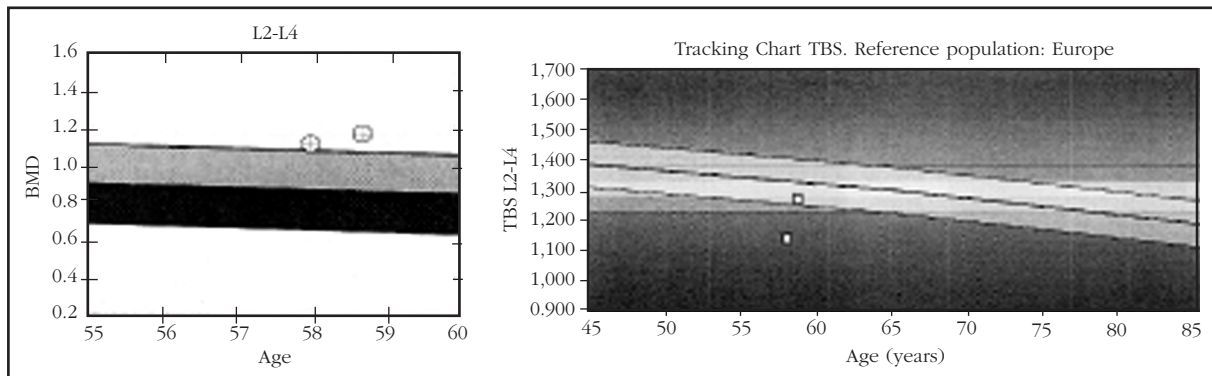


Figure 2. Evolution of the DXA (BMD and TBS) in lumbar spine one year after surgery



- parathyroidectomy, for asymptomatic primary hyperparathyroidism: a prospective, randomized trial. *J Clin Endocrinol Metab* 2007;92:1687-92.
- Bollerslev J, Marcocci C, Sosa M, Nordenstrom J, Bouillon R, Mosekilde L. Current evidence for recommendation of surgery, medical treatment and vitamin D repletion in mild primary hyperparathyroidism. *Europ J Endocrinol* 2011;165:851-64.
 - Bollerslev J, Ogard CG, Schwarz P, Vestergaard H, Vestergaard P. Primary hyperparathyroidism-occurrence, symptoms, complications and treatment. *Ugeskr Laeger* 2005;167:910-4.
 - Consensus Development Conference Statement. *J Bone Miner Res* 1991;6:S9-S13.
 - Bandeira F, Cusano NE, Silva BC, Cassibba S, Almeida CB, Machado VC, et al. Bone disease in primary hyperparathyroidism. *Arq Bras Endocrinol Metabol* 2014;58:553-61.
 - Bilezikian JP, Khan AA, Potts JT Jr, Third International Workshop on the Management of Asymptomatic Primary H. Guidelines for the management of asymptomatic primary hyperparathyroidism: summary statement from the third international workshop. *J Clin Endocrinol Metab* 2009;94:335-9.
 - Bilezikian JP, Potts JT, Jr, Fuleihan Gel H, Kleerekoper M, Neer R, Peacock M, et al. Summary statement from a workshop on asymptomatic primary hyperparathyroidism: a perspective for the 21st century. *J Clin Endocrinol Metab* 2002;87:5353-61.
 - Bilezikian JP, Potts JT Jr, Fuleihan Gel H, Kleerekoper M, Neer R, Peacock M, et al. Summary statement from a workshop on asymptomatic primary hyperparathyroidism: a perspective for the 21st century. *J Bone Miner Res* 2002;17 Suppl 2:N2-11.
 - Silverberg SJ, Clarke BL, Peacock M, Bandeira F, Boutroy S, Cusano NE, et al. Current issues in the presentation of asymptomatic primary hyperparathyroidism: proceedings of the Fourth International Workshop. *J Clin Endocrinol Metab* 2014;99:3580-94.
 - Bollerslev J. The important players in primary hyperparathyroidism. *Clin Endocrinol* 2013;79:774-5.
 - Roux JP, Wegrzyn J, Boutroy S, Bouxsein ML, Hans D, Chapurlat R. The predictive value of trabecular bone score (TBS) on whole lumbar vertebrae mechanics: an ex vivo study. *Osteoporos Int* 2013;24:2455-60.
 - Silva BC, Leslie WD, Resch H, Lamy O, Lesnyak O, Binkley N, et al. Trabecular bone score: a noninvasive analytical method based upon the DXA image. *J Bone Miner Res* 2014;29:518-30.
 - Romagnoli E, Cipriani C, Nofroni I, Castro C, Angelozzi M, Scarpiello A, et al. "Trabecular Bone Score" (TBS): an indirect measure of bone micro-architecture in postmenopausal patients with primary hyperparathyroidism. *Bone* 2013;53:154-9.
 - Silva BC, Boutroy S, Zhang C, McMahon DJ, Zhou B, Wang J, et al. Trabecular bone score (TBS)--a novel method to evaluate bone microarchitectural texture in patients with primary hyperparathyroidism. *J Clin Endocrinol Metab* 2013;98:1963-70.
 - Eller-Vainicher C, Filopanti M, Palmieri S, Ulivieri FM, Morelli V, Zhukouskaya VV, et al. Bone quality, as measured by trabecular bone score, in patients with primary hyperparathyroidism. *Europ J Endocrinol* 2013;169:155-62.
 - The American Association of Clinical Endocrinologists and the American Association of Endocrine Surgeons position statement on the diagnosis and management of primary hyperparathyroidism. *AACE/AAES Task Force on Primary Hyperparathyroidism. Endocr Pract* 2005;1:49-54.5

Merino M, Vega B, Guijarro G, Navea C, Torán C, Civantos S

Servicio de Endocrinología y Nutrición - Hospital Universitario de Getafe (Madrid)

Familial hypocalciuric hypercalcemia: sometimes it is not what it seems

Correspondence: María Merino Viveros - Hospital Universitario de Getafe - Servicio de Endocrinología y Nutrición - Carretera de Toledo km 12,500 - 28905 Getafe - Madrid (Spain)

e-mail: marietta84@hotmail.com

Date of receipt: 05/03/2015

Date of acceptance: 24/03/2015

Summary

Familial hypocalciuric hypercalcemia (FHH) is an uncommon cause of hypercalcemia. Its prevalence is estimated to be 1:78,000 people. We describe a case with atypical presentation confirmed by genetic diagnosis. This is a case of a woman of 74 years of age with osteoporosis referred to the endocrinology service with suspected primary hyperparathyroidism (HPTP). She presented with a high level of parathyroid hormone (96.3 pg/ml, normal limits (NL): 15-65 pg/ml), with normal levels of calcium, phosphorus and magnesium, as well as a raised level of calciuria.

She subsequently presented with normal levels of PTH, raised levels of calcium, combined with normal-high calciuria. The calcium/creatinine clearance ratio (CCCR, in mmol/l) varied between 0.011 and 0.02 mmol/l. A CCCR <0.01 is suggestive of FHH, and a CCCR >0.02, of HPTP. This ratio is within the range between 0.01 and 0.02 mmol/l, a reason which justifies requesting a genetic test in all patients with normal or high PTH, hypercalcemia and CCCR <0.02, requirements which our index case meets.

Key words: *familial hypocalciuric hypercalcemia, primary hyperparathyroidism, CaSR, calcium/creatinine clearance ratio (CCCR).*

Introduction

Hypercalcemia is a common finding in clinical practice. Among the different causes are primary hyperparathyroidism (PHPT) and tumour-induced hypercalcemia, which represent more than 90% cases, but there are also others such as vitamin D intoxication, granulomatous diseases, drugs such as thiazides and lithium, hyperthyroidism and familial hypocalciuric hypercalcemia (FHH). This last condition represents a benign cause of dominant autosomal hereditary hypercalcemia which does not usually require treatment. In most cases FHH is the result of mutations which inactivate the calcium sensing receptor (CaSR)¹. Its prevalence is estimated as being 1:78,000 persons², but it is assumed that it must be higher since there are many cases which are not detected. Patients usually present with light-to-moderate hypocalciuria, inappropriately normal levels of parathyroid hormone (PTH) and normal or high levels of magnesium. Below, we present a case which did not suggest initially that related to this pathology, but its clinical development, diagnoses of family members, and lastly, a genetic study, confirmed the diagnosis for us.

Presentation of the Case

A case of a woman of 74 years of age with type 2 diabetes, with arterial hypertension (AHT) in treatment with losartan, and with postmenopausal osteoporosis diagnosed at 68 years of age in the rheumatology clinic in treatment with alendronate weekly (bone densitometry: T-score femoral neck -1.3 SD and lumbar spine -3.9 SD). She was referred to the endocrinology clinic because in this context she presented with high PTH, with normal levels of calcium, phosphorus and magnesium, as well as a high level of calciuria (Table 1).

In this first evaluation the condition was labelled as hypercalciuria with high PTH without hypercalcemia to be studied, with the possible diagnosis of normocalcemic PHPT.

The study was widened and the bisphosphonate was stopped for 3 months before carrying out a baseline study, with successive analyses seeing normal rates of PTH with raised levels of blood calcium, phosphorus and magnesium within the normal range. At the start of the follow up she presented high calciuria which subsequently normalised without becoming low. A parathyroid gamma-graphy was also carried out, which was negative. The calcium/creatinine clearance ratio (CCCR, in mmol/l) was calculated, which varied between 0.011 and 0.02, not being clearly lower than 0.01, a finding which characterises FHH. Therefore, we had a patient with light-to-moderate hypercalcemia, with normal levels of PTH, and with calciuria which was initially high and which then normalised during the follow up. Secondary causes which could be inferred from Ca/PTH levels, such as vitamin D deficit, renal insufficiency and treatment with thiazides or bisphosphonates were excluded.

During the follow up, the patient's nephew and niece (her sister's children) were diagnosed with FHH, with compatible genetic studies. With

all this data a genetic study of our index case was requested, showing the following result: "by sequencing the CaSR gene situated in chromosome 3q 21-25, the patient presented a mutation of exon 7 consisting of c.2089 G>A; p. val697 Met. The patient studied presented this alteration heterozygously".

In approximately 65% of cases FHH is the result of an inactive mutation in CaSR, whose genes reside in the long arm of chromosome 3 (3q21.1). This form of FHH is called FHH 1³, and is the form present in our patient. FHH2 derives from inactive mutations of the protein G alpha 11 (19p): a guanine-binding protein which bonds with CaSR to activate the phospholipase C, which contributes to the inhibition of the release of PTH when the concentrations of extracellular calcium are raised. Lastly, FHH3 is linked with mutations in AP2S1 (19q13).

To date, around 200 mutations in CaSR associated with FHH have been described (<http://www.casrdb.mcgill.ca>). In addition, there is evidence that the biochemical severity of the FHH is specific to the mutation^{4,5}, and hence the heterogeneity of the FHH genotypes result in different phenotypes, above all with respect to the calciuria. While hypocalciuria is the classic finding of FHH, hypercalciuria has been seen in families with a confirmed genotype of FHH⁶. In FHH, hypercalcemia does not usually have clinical consequences, but there are cases described in which it has been associated with pancreatitis, chondrocalcinosis, nephrolithiasis, and other symptoms associated with PHPT⁷.

The clinical guides recognise CCCR as the biochemical index of choice to differentiate between PHPT and FHH⁸. A ratio <0.01 is suggestive of FHH and >0.02 of PHPT. CCCR is limited within the range 0.01 and 0.02, which is the situation we found in our case. This test has a sensitivity of 80% and a specificity of 88% for the diagnosis of FHH, which has resulted in the suggestion that the diagnosis should be carried out in two steps⁹: requesting a genetic test in all patients with normal or high PTH, hypercalcemia and CCCR <0.02, requirements with which our index case complied. Although limited in its specificity and sensibility CCCR may alert the doctor to the possible presence of FHH even with a 3 normal 2 level of 24 hour urinary calcium secretion¹⁰.

HFF is an uncommon condition, and on occasion its clinical presentation overlaps with PHPT, which is much more common. The excretion of calcium in urine over 24 hours may be low, normal or high in both pathologies, which means that the diagnosis can be confused. It should be taken into account that CCCR may help to differentiate between the two conditions, and that the genetic test to determine mutations in the CaSR is the only sure diagnostic method, even though these tests are not sensitive in 100% of cases, and that a careful evaluation of the family history may be required in order to confirm or reject the diagnosis, even with a negative result in the genetic test.

Table 1. Changes in biochemical parameters during follow-up

	Creatinine	Total calcium	PTH	Calciuria	CCCR
Normal limits	0.5-1.2 mg/dl	8.5-10.5 mg/dl	15-65 pg/ml	50-250 mg	^a mmol/l
Initial assessment (1 st visit)	0.6	10.4	96.3	483.2	0.014
3 months without bisphosphonate (2 nd visit)	0.7	11.2	61	474.2	0.02
Subsequent consultations ^b	0.6±0.08	10.7±0.3	48.5±12	213±93	0.014±0.003

^a CCCR: clearance calcium/creatinine clearance: (Calcium urine x Creatinine plasma)/(Calcium plasma x Creatinine urine); ^b Values expressed as mean ± SD according to the reviews in the 2 years later.

* Not included in the table the values of magnesium (Mg) and phosphorus (P) plasma, and that at all times remained within normal limits (Mg: 1,7-2.5 mg/dl y P: 2.5-4.5 mg/dl).

In conclusion, it should be borne in mind that, when presented with slight hypercalcemia doctors should think of the possibility that they are dealing with FHH, because, in spite of its name, hypercalcemia may be neither familial nor hypocalciuric. CCCR, combined with genetic tests may help us avoid erroneous diagnoses and unnecessary surgery for the patient.

Bibliography

- Christensen SE, Nissen PH, Vestergaard P, Mosekilde L. Familial hypocalciuric hypercalcemia: a review. *Curr Opin Endocrinol Obes* 2011;18:359-70.
- Hinnie J, Bell E, McKillop E, Gallacher S. The prevalence of familial hypocalciuric hypercalcemia. *Calcif Tissue Int* 2001;68:216-8.
- Hannan FM, Nesbit MA, Zhang C, Cranston T, Curley AJ, Harding B, et al. Identification of 70 calcium-sensing receptor mutations in hyper- and hypo-calcaemic patients: evidence for clustering of extracellular domain mutations at calcium-binding sites. *Hum Mol Genet* 2012;21:2768-78.
- Hendy GN, Guarnieri V, Canaff L. Calcium-sensing receptor and associated diseases. *Prog Mol Biol Transl Sci* 2009;89:31-95.
- Ward BK, Magno AL, Blitvich BJ, Rea AJ, Stuckey BG, Walsh JP, et al. Novel mutations in the calcium-sensing receptor gene associated with biochemical and functional differences in familial hypocalciuric hypercalcemia. *Clin Endocrinol (Oxf)* 2006;64:580-7.
- Warner J, Epstein M, Sweet A, Singh D, Burgess J, Stranks S, et al. Genetic testing in familial isolated hyperparathyroidism: unexpected results and their implications. *J Med Genet* 2004;41:155-60.
- Law WM Jr, Heath H III. Familial benign hypercalcemia (hypocalciuric hypercalcemia). Clinical and pathogenetic studies in 21 families. *Ann Intern Med* 1985;102:511-9.
- Bilezikian JP, Potts JT Jr, Fuleihan GH, Kleerekoper M, Neer R, Peacock M, et al. Summary statement from a workshop on asymptomatic primary hyperparathyroidism: a perspective for the 21st century. *J Clin Endocrinol Metab* 2002;87:5353-61.
- Christensen SE, Nissen PH, Vestergaard P, Heickendorff L, Brixen K, Mosekilde L. Discriminative power of three indices of renal calcium excretion for the distinction between familial hypocalciuric hypercalcemia and primary hyperparathyroidism: a follow-up study on methods. *Clin Endocrinol (Oxf)* 2008;69:713-20.
- Shinall MC Jr, Dahir KM, Broome JT. Differentiating familial hypocalciuric hypercalcemia from primary hyperparathyroidism. Review article. *Endocr Pract* 2013;19:697-702.

Lisa Gracia M, Córdoba Alonso AI, Pérez Núñez MI, Hernández Hernández JL

Unidad de Metabolismo Óseo - Servicio de Medicina Interna - Servicio de Traumatología y Cirugía Ortopédica - Hospital Marqués de Valdecilla-IDIVAL.
Universidad de Cantabria-RETICEF - Santander

Multiple osteonecrosis as a form of presentation of osteogenesis imperfecta

Correspondence: José Luis Hernández Hernández - Hospital Marqués de Valdecilla - Unidad de Metabolismo Óseo - Avda. Valdecilla, s/n - 39008 Santander (Spain)
e-mail: hernandezjluis@gmail.com

Date of receipt: 12/03/2015

Date of acceptance: 25/03/2015

Summary

The case of a woman diagnosed with osteogenesis imperfecta, who presented with multiple osteonecrosis, is described. To our knowledge, this is the first reported case of such a clinical presentation. The therapy, as well as the outcome for the patient, is also analysed.

Key words: *osteogenesis imperfecta, osteonecrosis, teriparatide, denosumab.*

Introduction

Osteogenesis imperfecta (OI) is a congenital disease of the connective tissues, of autosomal dominant inheritance, which affects the gene for collagen type 1, present in many tissues such as bone, tendons, ligaments and sclera. The disease is classified in various types, from type I (the most frequent and lightest) and type II (lethal at birth), to types III, IV, V, VI and VII which present phenotypes of varying intensity from moderate to severe¹.

The principal clinical manifestations of OI are recurrent fractures and secondary bone deformities. Dentinogenesis imperfecta and a blue colouration of the sclera are also common characteristics of this disease². Its diagnosis is based on its clinical manifestations and on the presence of family antecedents. The administration of calcium and vitamin D, and the bisphosphonates, are the basis of treatment³.

On the other hand, primary or idiopathic osteonecrosis has been related with fractures due to an insufficiency in the chondral bone. Unlike the secondary form, there are usually no predisposing factors and the disease is associated with the female sex, advanced age and obesity. The diagnostic text of choice is nuclear magnetic resonance (NMR), with a hyposignal in the bone marrow at T sequences and a hypersignal in the STIR sequences or for fat saturation T²⁴.

We present the case of a patient with osteogenesis imperfecta, which made its first appearance as multiple osteonecrosis. To our knowledge, this is the first case described in the literature of this form of presentation of the disease. The treatment administered and the development of the patient are analysed.

Presentation of Case

A woman of 47 years of age without toxic habits, known drug allergies, or relevant medical conditions. She attended hospital in January 2010 due to the presence of pain in the right ankle over the previous year, which increased with load and which was accompanied by flogotic signs. A bone gammagraphy was carried out, as well as an NMR which showed an intense bone oedema with severe loss of mineral density, suggestive of osteonecrosis of the astragalus bone with associated articular leaking (Figure 1A). Treatment with intravenous pamidronate was initiated, but the patient presented high fever following the infusion, for which reason the administration was halted. Tramadol, diclophenac and rehabilitation treatment were prescribed, without evident easing of the pain. In September 2010 she reported intense pain in the right inguinal region, which increased when walking. An NMR scan was performed in both hips with avascular necrosis being observed in the right femoral head, stage I-II in the FICAT classification (Figure 1C). Treatment was initiated with oral gabapentin (600mg/8 hours), and she was referred to a bone metabolism unit. In the physical examination in our clinic what drew our attention was the presence of blue sclerae (Figure

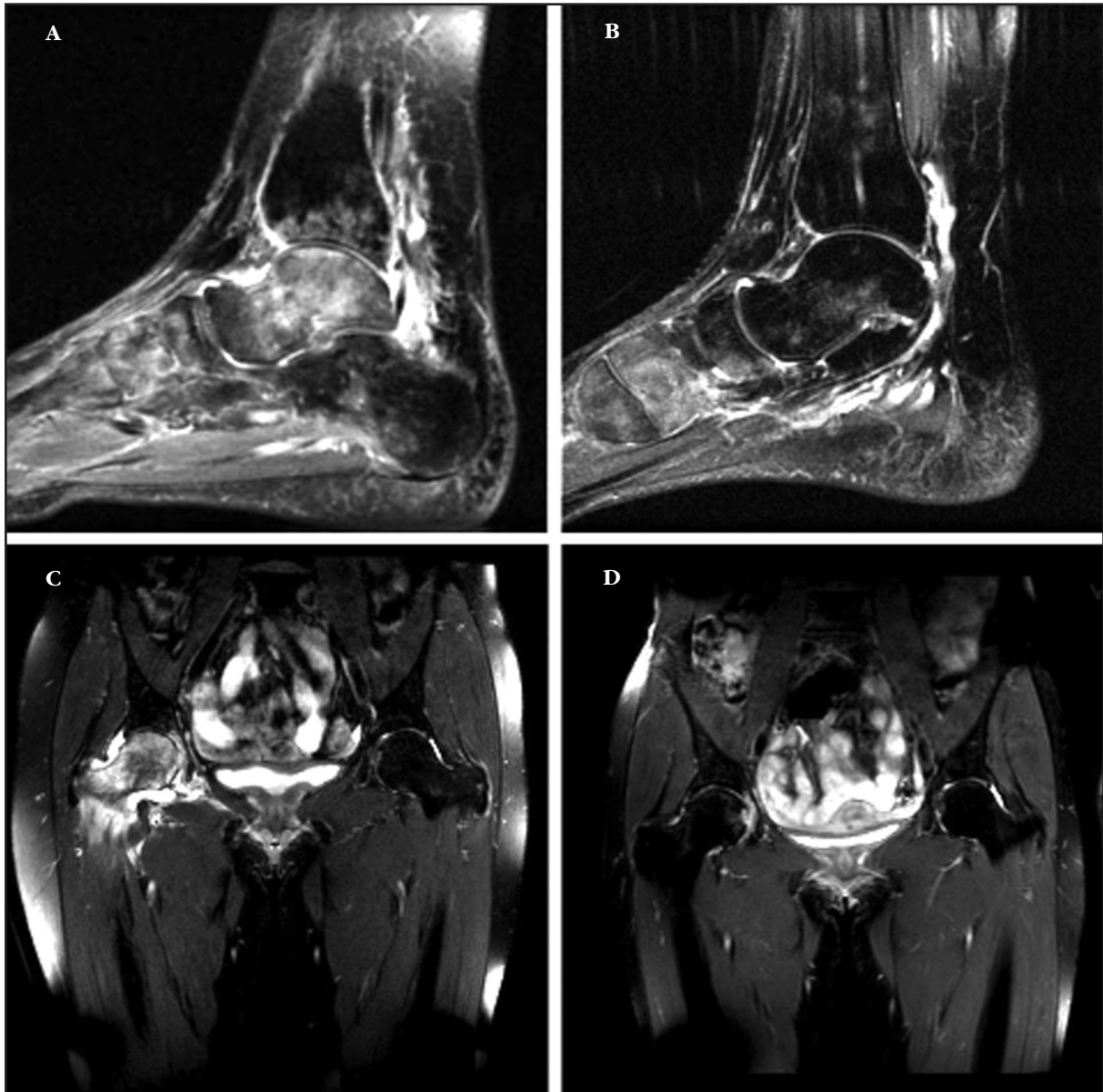
2). On questioning the patient again, she indicated that her mother had had multiple fractures from the age of 49, which immobilised her. A brother and two maternal aunts had suffered early hip fractures. The densitometer showed serious osteoporosis in the three usual locations (lumbar spine: T-score=-3, Z-score=-1.8; femoral neck: T-score=-3.1, Z-score=-2.3 and total hip: T-score=-2.7, Z-score=-2.0). The calciuria was 336 mg/dl, levels of 25(OH) vitamin D 11 ng/ml and intact PTH, 49 pg/ml. The markers for bone remodelling were clearly high (CTX: 1.036 ng/ml). Given the clinical findings and the family history, the diagnosis of osteogenesis imperfecta type I was established. The audiometry showed a minimal fall in the acute tones. Treatment was initiated with calcium (1,000 mg/day), vitamin D (800 UI/day) and risedronate (35 mg/week), in January 2011. In March of that year the risedronate was changed for subcutaneous teriparatide (20 mcg/day) due to digestive intolerance. In May 2011 an NMR check showed a clear reduction in the bone oedema and in the articular leaking in the ankle, as well as in the oedema in the bone marrow of the right hip (Figures 1B and 1D). The patient completed 24 months with teriparatide without complications and with progressive clinical improvement. The markers for bone formation remained high during the treatment (amino-terminal propeptide of procollagen type 1 –PINP-: 45 ng/ml; osteocalcin: >100 ng/ml), as did the levels of 25 (OH) vitamin D. In March 2013 treatment was initiated with denosumab (60 mg/6 months), the patient presenting satisfactory clinical and radiological development. In the last consultation, in January 2015, the markers for remodelling were suppressed (PINP: 5.8 ng/ml; carboxy-terminal telopeptide of collagen type 1–CTX-: <0.030 ng/ml) and levels of 25 (OH) vitamin D of 31 ng/ml. The bone mineral density (BMD) level was not significantly reduced with respect to the baseline figure (lumbar spine: T-score=-3.1 and Z-score=-1.5; femoral neck: T-score=-3.2 and Z-score=-2; total hip: T-score=-3 and Z-score=-2), but the patient had suffered no fractures or osteoporosis in the follow up period.

Discussion

Osteogenesis imperfecta is the most common congenital disease of bone tissue 1. We believe that our case has special interest due both to the unusual form of presentation (osteonecrosis of ankle and hip) and the clinical and radiological response to the treatment received.

The osteonecrosis was interpreted as being primary, given that the patient did not have any predisposing factors and had not received any treatment which might impact on the bone. We are not able to discount, as a hypothesis, the possibility that the osteonecrosis may have been secondary to the patient's OI, taking into account the fact that the microscopic alterations in the trabecular bone characteristic of this genetic disease may be associated with lesions of ischemic origin typical of osteonecrosis.

Figure 1. MRI of the ankle and right hip. Associated osteonecrosis of the talus with before (panel A) and after treatment (panel B) bone edema. Avascular necrosis of femoral head right marrow edema (panel C) and after treatment (panel D)



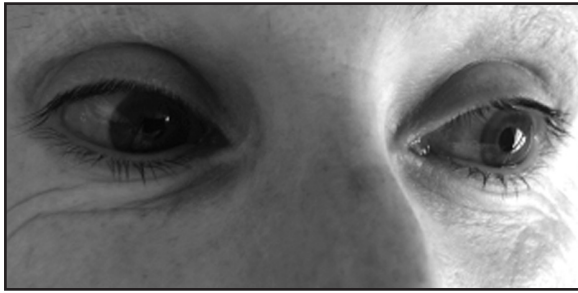In our patient, due to her serious necrosis, treatment was initiated with bisphosphonates, which were withdrawn due to an adverse reaction (pamidronate) or digestive intolerance (risedronate). For this reason, a sequential combination of teriparatide and denosumab were administered, with an excellent clinical and radiological response in the patient's osteonecrosis.

The bisphosphonates are the first option for treatment of OI and, although its efficacy has been demonstrated in children, studies in adults are scarce⁵. In general terms, the treatment is the same as that for osteoporosis, even though the fact that the physiopathology of the two diseases is different needs to be taken into account. While in osteoporosis a loss of bone mass predominates, in OI an alteration in the bone matrix is prevalent, which

could explain that lack of efficacy of these drugs in the prevention of fractures in some cases of OI⁶.

In this respect, the therapeutic alternatives available to us are few. The use of teriparatide in light forms of OI has been suggested in some works, but without conclusive data. Thus, Orwol et al. analysed the efficacy of this drug in adults with OI type I, observing a significant increase in BMD in the lumbar spine and hip, although no differences were observed in the risk of fracture compared with the group which received the placebo⁷. Gatti et al., studied 13 postmenopausal women with OI who had received treatment with neridronate over two years and had suffered a fracture during this period. Teriparatide was administered to them for 18 months with a significant increase being observed compared with the base-

Figure 2. Bluish sclerae



line value in the lumbar spine but not in the hip, data similar to those found in our patient. The authors suggest the possibility that the treatment with teriparatide is not that effective in terms of increasing the BMD, as is the case in postmenopausal or senile osteoporosis⁸.

At the present time, biological drugs are being evaluated for the treatment of OI, such as denosumab or anti-sclerostin antibodies, as well as gene therapies based on mother cells⁹.

With respect to treatment with denosumab, there are studies which have been carried out in children with OI type VI. This condition is characterised by an autosomal recessive mutation in the SERPINF1 gene, which leads to the activation of the osteoclasts through the RANK/RANKL pathway, which has resulted in the use of denosumab as an alternative to treatment with bisphosphonates in those patients who have a poor response to them¹⁰. Our patient presented a good clinical development, with stability in BMD and a congruent response in the markers for bone remodelling, after the prescription of teriparatide and, subsequently, denosumab. Furthermore, the osteonecrosis in the hip improved in the radiological checks which were carried out.

In the light of this case, and the literature review, the use of teriparatide, followed by denosumab in patients with OI and intolerance to, or adverse effects with, the bisphosphonates, could be taken into consideration.

Bibliography

1. Warman ML, Cormier-Daire V, Hall C, Krakow D, Lachman R, LeMerrer M, et al. Nosology and classification of genetic skeletal disorders: 2010 revision. *Am J Med Genet* 2011;155:943-68.
2. Van Dijk FS, Sillence DO. Osteogenesis imperfecta: clinical diagnosis, nomenclature and severity assessment. *Am J Med Genet* 2014;164:1470-81.
3. Khosla S, Bilezikian JP, Dempster DW, Lewiecki EM, Miller PD, Neer RM, et al. Benefits and risks of bisphosphonate therapy for osteoporosis. *J Clin Endocrinol Metab* 2012;97:2272-82.
4. Guillermo Fernández-Cantón. Del edema de la médula ósea a la osteonecrosis. *Nuevos conceptos. Reumatol Clin* 2009;5:223-7.
5. Shapiro JR, Thompson CB, Wu Y, Nunes M, Gillen C. Bone mineral density and fracture rate in response to intravenous and oral bisphosphonates in adult osteogenesis imperfecta. *Calcif Tissue Int* 2010;87:120-9.
6. Lindahl K, Langdahl B, Ljunggren Ö, Kindmark A. Treatment of osteogenesis imperfecta in adults. *Eur J Endocrinol* 2014;171:79-90.
7. Orwoll ES, Shapiro J, Veith S, Wang Y, Lapidus J, Vanek C, et al. Evaluation of teriparatide treatment in adults with osteogenesis imperfecta. *J Clin Invest* 2014;124:491-8.
8. Gatti D, Rossini M, Viapiana O, Povino MR, Liuzza S, Fracassi E, et al. Teriparatide treatment in adult patients with osteogenesis imperfecta type I. *Calcif Tissue Int* 2013;93:448-52.
9. Millington-Ward S, McMahon HP, Farrar GJ. Emerging therapeutic approaches for osteogenesis imperfecta. *Trends Mol Med* 2005;11:299-305.
10. Semler O, Netzer C, Hoyer-Kuhn H, Becker J, Eysel P, Schoenau E. First use of the RANKL antibody denosumab in osteogenesis imperfecta type VI. *J Musculoskelet Neuronal Interact* 2012;12:183-8.

Sabonet-Morente L¹, Carrasco-Catena A¹, Castro A², González M², Cano A^{2,3}

1 Servicio de Obstetricia y Ginecología - Hospital Universitario Dr. Peset - Valencia

2 Servicio de Obstetricia y Ginecología - Hospital Clínico Universitario - Valencia

3 Departamento de Pediatría - Obstetricia y Ginecología - Universidad de Valencia

Regulation of bone modifications in the mother during pregnancy

Correspondence: Antonio Cano - Departamento de Pediatría, Obstetricia y Ginecología - Facultad de Medicina - Avda. Blasco Ibáñez, 15 - 46010 Valencia (Spain)
e-mail: Antonio.cano@uv.es

Date of receipt: 19/11/2014

Date of acceptance: 20/01/2015

Summary

Pregnancy defines a model where the development of the fetal skeleton occurs in a short lapse of time. This achievement is accomplished under the control of the own fetus, who regulates the process through the signals generated in the so-called feto-placental unit. The maternal organism undergoes an adaptation process in which a drastic readjustment of mechanisms involved in the bone turnover takes place. Among the most obvious changes detected in maternal blood there are the increases in calcitriol, placental growth hormone, insulin-like growth factor -1 (IGF-1), estrogens and prolactin. There are also increases in osteoprotegerin and in the ligand of the receptor activator of nuclear factor kappa (RANKL). The phenomenon leads to transitory states of bone deterioration, which extends up to the end of lactation. The whole process is still insufficiently explored. We present an update of the changes affecting the mother and of those that arise in the placenta.

Key words: *pregnancy, bone, mother, regulators.*

Introduction

The body of the pregnant mother goes through a combination of changes to accommodate itself to the conditions imposed by the presence of the fetus and its needs. The driver of these changes is the fetoplacental unit, which acts as a focus of the emission of signals to the mother's organs and systems. In some cases deficiencies in these changes result in pathologies, such as vascular dysfunctions underlying high blood pressure and preeclampsia-related proteinuria, among others.

The bone is not immune to the need for change, due, among other factors, to the fact that the foetal ossification requires the transfer of large quantities of calcium, above all in the third trimester. The final weeks are characterised by an acceleration in the growth and calcification of the foetal skeleton, which takes advantage of most of the on average 30 g of calcium transferred from the mother through the placenta. Curiously, the calcium transfer occurs against the gradient, since the foetus lives in a hypercalcaemic environment in comparison with the mother¹.

The transfer of calcium does not occur without having an impact on the mother's bone. There is a debate as to whether it causes a more or less significant period of decalcification, which may even result in there being a window of susceptibility to fracture. There are a significant number of publications, clinical cases or case series which support of this view, containing information about fragility fractures in pregnant or breastfeeding women². The transitory nature of the process can, in any case, be deduced from the lack of evidence associating pregnancy with the risk of osteoporosis in the long term. Therefore, whatever the impact may be, there is a subsequent recuperation of the bone. This phenomenon has been seen in data from densitometric studies, which show a progressive recuperation. It remains to be clarified whether this recuperation is specific to the state of pregnancy or not. In fact, a similar restoration in the deterioration of bone mass has been reported which is found in hypo-estrogenic states concomitant with birth control with systemic gestagens such as medroxyprogesterone acetate³, but it appears less clear when the hypoestrogenism is associated with endocrine pathology, such as hypogonadotropic hypogonadism⁴.

The endocrine regulators which control changes in bone metabolism in the mother during pregnancy are still not sufficiently well-understood. For example, there is an open debate about the possible role of vitamin D, and therefore, as to whether to supplement this vitamin or not. The details regarding the mediators generated in the fetoplacental unit are also not well-understood.

Here we present the most important features of this theme which is also very interesting to researchers in perinatology.

Is there deterioration in bone during pregnancy?

This first question arises in the context of the readjustment of the mother's body, which uses many compensatory systems. It cannot be discounted,

therefore, that the draining of calcium through the placenta may take place without affecting the maternal skeleton if there are sufficiently powerful compensatory systems in place. An increase in the intestinal absorption of calcium, for example, could be an option if it reaches a sufficient level, as is mentioned in the section regarding vitamin D.

However, although this issue is not beyond dispute, everything appears to suggest that there is a net loss of calcium in the mother. The evaluation strategies have been limited by a refusal to carry out densitometric examinations in pregnant women, in spite of their low radiation dose, and by the continuous changes in blood volume and glomerular filtrate, which reduce the values of the biochemical markers for bone turnover. There are histological studies of bone biopsies, but they are relatively old and not very clear in their interpretation⁵. There are also experimental models, in rodents and primates, which do not always correspond with histological data in humans⁶. In spite of this, the most recent studies have carried out densitometries immediately pre- and post-pregnancy, or have included examinations of peripheral regions, such as the forearm, during pregnancy⁷. Furthermore, although with different technology, systems based on ultrasound have been used by various authors⁸.

The findings of some studies suggest that there is a deterioration in those factors studied, be it bone mineral density or parameters evaluated by ultrasound, sound velocity transmission, broad band attenuation or rigidity modulus⁸. Therefore, the results are consistent with what is known about rates of calcium transfer: there are slight adjustments during the first half of pregnancy, but bone resorption is accelerated in the third trimester, well above the rate of formation, although this also increases.

Endocrine correlate

As has already been said, the maternal changes have their principal origin in the fetoplacental unit, the real driver for all these changes. However, on some occasions the connection between the signals originating in the fetoplacenta and the modifications in the regulators of calcium metabolism in the mother are not known. One of the clear cases is that of vitamin D. In other cases there are agents which, on the contrary, clearly originate in the placenta, and which impact on the maternal systems. The placenta growth hormone (PGH) is a good example of this. The most evident changes are described below (summarised in Table 1).

Regulators originating in the mother

Parathyroid hormone and parathyroid hormone-related peptide

Parathyroid hormone (PTH) has received much attention as a consequence of its great pro-resorptive potential. Its action in liberating significant amounts of calcium from the bone would be consistent with observations regarding the transfer of

significant quantities of the cation through the placenta, with the consequent deterioration of bone mass in the mother. The increase in intestinal absorption and the characteristic hypocalcaemia in pregnancy would support this interpretation.

However, in spite of the attractiveness of this hypothesis, the maternal PTH is not currently considered a determining factor. There has been a debate about circulatory changes, with substantial increases reported in tests subsequently considered to have been defective. Better technologies based on the use of antibodies, which are more reliable, suggest that PTH undergoes little change in pregnancy, and that its involvement in the adjustments in bone metabolism is probably of little importance⁹.

Because of its theoretical proximity PTH-related peptide (PTHrP) has been proposed as another determining factor. The debate about the methodological difficulties in reliable measurement are also reproduced here. The influence that the isoforms of the molecule, or the heterogeneity of the region recognised by the antibodies, have on this have recently been reviewed². To date, there are still questions to be answered, with isolated data which suggest an increase in the final phases of pregnancy. Its potential is not negligible, as the finding of pathological hypercalcaemia as a consequence of an abnormally high production of PTHrP suggests¹⁰.

Vitamin D

Vitamin D is receiving particular attention. Its role in bone metabolism during pregnancy is still largely unknown. Its possible participation, however, is potentially attractive since, in increasing the intestinal absorption of calcium, it appears to be a candidate for supplying the maternal body with a substantial portion of that lost through the placenta.

There is already a notable increase in the levels of calcitriol (1,25 (OH)₂ vitamin D) from the first trimester, and especially in the second half of pregnancy. This increase is parallel to the intestinal absorption of calcium. The increase in the enzyme activity of renal 1 α -hydroxylase is key to this change, given that the increase in calcitriol is not found in a pregnancy in an anephric woman¹¹. Minor roles in the supply of 1 α -hydroxylase would be taken by the placenta, decidua, and possibly the fetus' own kidney.

Combined with this there is what appears to be an almost universal phenomenon, a high prevalence of blood levels of 25-OH vitamin D considered as insufficient in pregnant women in all latitudes of the globe^{12,13}. In the lowest socioeconomic groups, at least in our country, the situation is especially dramatic¹⁴.

The modulating role which the vitamin D binding protein may have is not clear. As in all hyperestrogenic states, its concentration rises during pregnancy, but it remains to be determined to what extent it regulates the activity of vitamin D in this context. We would therefore be dealing with a crucial element in the system. In favor of this

view is a series of studies which supplemented vitamin D and which gave results which support the idea of vitamin D as a key element in the programming of intra-uterine fetal bone growth. We would not now be talking about bone mineral density, but rather a new dimension, which is that of fetal growth¹⁵. However, the participation of vitamin D has been disputed by experimental models in rodents lacking vitamin D or its receptor, in which, curiously, the increase in intestinal absorption of calcium was similar to the controls¹⁶. It is not known whether or not these models reproduce the situation in humans.

Changes have been reported in other regulators such as calcitonin, but their impact appears slight.

Regulators produced in the feto-placental unit *PGH*

PGH is a clear example of the transfer of modulators from the feto-placental unit to the mother, since it is produced in the syncytiotrophoblast but only circulates in the mother's blood. It is detected from the first trimester and from then the increase does not cease until the end of pregnancy. It plays a direct role in providing nutrients to the placenta, but it is not known what is the exact magnitude of its potential as regulator of insulin-like growth factor type 1 (IGF-1) in the mother. The details of the action of this on the bone has not been specifically investigated in pregnancy. It is also not yet clear which part of its action is endocrine, paracrine or both¹⁷.

Human placental lactogen (HPL)

Also called chorionic somatomammotropin, this is produced in the trophoblast from the very first moments of gestation. It is a protein hormone resulting from the expression of the GH gene cluster. This group, located in chromosome 17q, contains two genes which code for GH, one expressed in the hypophysis and the other in the placenta (which codes for PGH) and two other genes related to HPL¹⁸.

The genetic family relationship determines some common actions, essentially in the metabolic field. HPL plays a pro-lipolytic role, mobilising fatty acids with a potential impact on the energy of the mother and fetus, and on insulin resistance. This second action forms part of the pro-diabetogenic complex in pregnancy. The consequence of this is an increase in the glycemic, and protein, offer to the feto-placental unit. So, the HPL participates in the offer of nutrients to the fetus, and hence constitutes a promotor factor for fetal growth (see¹⁹ for review).

The possibility cannot be discounted that, as with PGH, HPL may regulate IGF1 and other elements of the group of insulin-like growth factors, even if in a less direct way than with PGH. The impact that this may have on the process of calcification of fetal bone to a separate magnitude from its growth is uncertain, as is, at present, the dissection of these two functions in relation to the same IGF1.

Table 1. Schema of the changes in the blood of the mother of agents which are potential modulators of bone turnover. The questioning signs indicate that the increase is only suspected (in the case of PTHrP) or that there is no certainty about the direction of the changes (sclerostin)

Modulators of bone turnover	1 st half pregnancy	2 nd half pregnancy
PTH	↔	↔
PTHrP	↔	↔/↑(¿?)
Vitamin D (calcitriol)	↑	↑↑↑
DBP	↑	↑↑
PGH	↑	↑↑↑
HPL	↑	↑↑↑
Estrogens	↑	↑↑↑
Prolactin	↑	↑↑↑
Osteoprotegerin	↔	↑
RANKL	↔	↑
IGF-1	↑	↑↑
Sclerostin	¿?	¿?

PTH: parathyroid hormone; PTHrP: PTH-related peptide; DBP: vitamin D bonding protein; PGH: placental growth hormone; HPL: human placental lactogen; RANKL: receptor activator of nuclear kappa-B factor ligand; IGF-1: insulin-like growth factor type 1.

PTH and PTHrP

The role played by PTH and PTHrP in fetoplacental unit could be considered to be at once both significant and cryptic. Contrary to data from the maternal blood, a series of observations whose only limitation is that they come from experimental models, suggest that the gradient pump which transfers calcium from the mother to the fetus works thanks to the active role of both peptides (reviewed in²). It is not known whether there is some kind of permeability between the fetal and maternal microenvironments as far as both hormones are concerned.

Estrogens

The estrogens are another agent produced in the placenta and exported to the maternal blood. Their powerful reductive effect on bone resorption is known, and their blood levels increase in parallel with that of the mass of the placenta, as the period of pregnancy increases. Therefore, their changes do not fit in to a context in which, as appears to occur in pregnancy, resorption in the mother increases in its final phase.

Prolactin

Also produced in the placenta and exported to the mother's blood, prolactin (PRL) may have an influence on metabolic changes in maternal bone. Data from rodents show that PRL acts on the osteoblasts, where the RANKL/OPG increases at the cost of lowering the OPG. This could therefore be a modulator consistent with the changes observed. However, it remains unclear whether or not this is similar in humans²⁰.

Mixed or of uncertain ascription

There are data showing changes in other regulators, such as the receptor activator of nuclear factor kappa-B ligand (RANKL), osteoprotegerin (OPG) or IGF-1. There is also a series of recent data related to the Wnt pathway. However, there is no certainty as to whether the contribution of the of the mother's body is significant if compared with the fetoplacental unit. Given the doubts which exist, they are included in this second block dedicated to factors of mixed or uncertain origin.

OPG exemplifies this imbalance between the two sections (Figure 1). Its maternal blood levels are stable until the final weeks when, paradoxically in relation to the increase in bone resorption, it rises²¹. The rapid decrease postpartum and the findings of high concentrations in the placenta and

membranes are interpreted as indicating that it is the placenta which is its main source²².

The changes in the levels of RANKL follow a similar pattern, but are less consistent due to the well-known methodological difficulties of measuring its blood levels^{23,24}.

The blood levels of IGF-1 increase as pregnancy progresses, but vary as a function of a number of variables, such as the mother's weight²⁵. Given the rich variety of functions of this growth factor, and the frequent contrast between its blood and tissue levels, there is no clear understanding of the relationship between these changes and those which the maternal skeleton undergoes.

Existing information regarding the role of the Wnt pathway, a system with a high osteo-anabolic capacity, in pregnancy is very scarce and inconclusive. In light of the data shown in the studies which have evaluated the impact on the bone of the regulation of sclerostin, a Wnt pathway inhibitor protein, its effect on the modifications in bone metabolism in the mother has been investigated. Sclerostin is produced in the osteoblasts and, given the difference in osteocytic mass bet-

ween the mother and the fetus, it should be the maternal section which is the territory in which any significant changes in sclerostin occurs. It has been found, however, that blood levels are higher in the umbilical cord than in the maternal blood. Interestingly, a direct relationship has been found between the blood levels of sclerostin in the umbilical cord and the density and mineral content of the fetal bone²⁶. The inhibitory effect of sclerostin on Wnt makes this this finding paradoxical, and its interpretation is still unclear. There is no reliable information regarding the progression of blood levels of sclerostin in the mother as pregnancy progresses. Given the scarcity of information and the difficulties in its interpretation it seems evident that this field needs to be investigated in more detail.

At a global level, this is a matter which has a great impact on later life, and fortunately there are various clinical studies which go beyond purely growth or bone health²⁷ and which include the impact on the risk of developing metabolic syndrome, respiratory disease, behavioural or other disorders (see²⁸ for the detailed review).

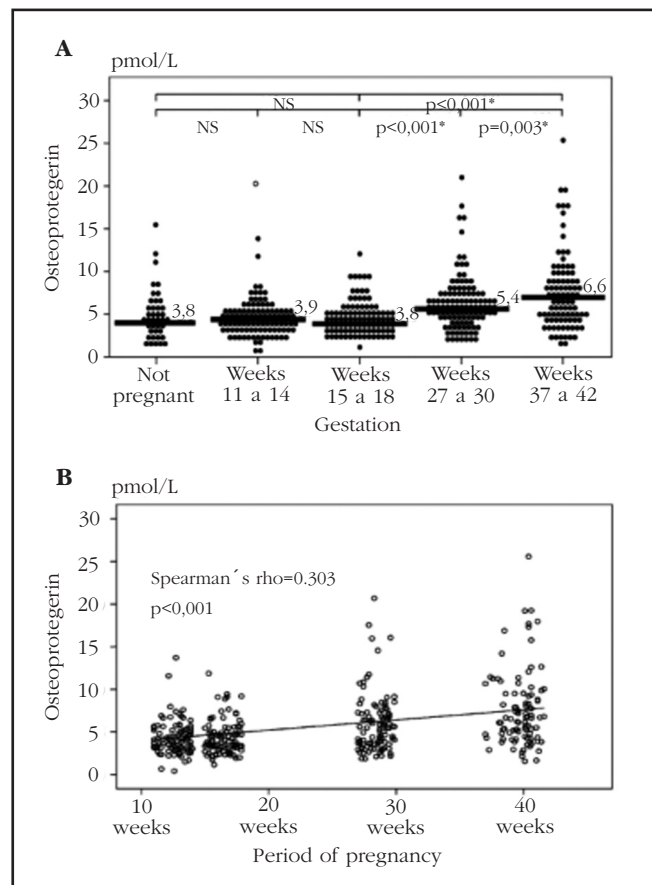
Conclusion

The impact of pregnancy on the maternal skeleton is still very poorly-understood, probably because there has not been any perception of there being a significant impact on maternal health. On the other hand, it is not known whether the changes which occur, be they in the mother, the feto-placental unit or both, may have implications beyond bone mineral density, and even affect fetal growth. As such, there are researchers who are investigating the possible role of vitamin D in this context^{15,29}. It is conceivable that improvements seen in experimental models and in diagnostic technology may help progress to be made in this field.

Bibliography

1. Kovacs CS. The role of vitamin D in pregnancy and lactation: insights from animal models and clinical studies. *Annu Rev Nutr* 2012;32:97-123.
2. Sanz-Salvador L, Garcia-Pérez MA, Tarín JJ, Cano A. ENDOCRINOLOGY IN PREGNANCY: Bone metabolic changes during pregnancy: a period of vulnerability to osteoporosis and fracture. *Eur J Endocrinol* 2014;10:1-40.
3. Lopez LM, Grimes DA, Schulz KF, Curtis KM, Chen M. Steroidal contraceptives: effect on bone fractures in women. *Cochrane Database Syst Rev* 2014;24:6: CD006033.
4. Hoffman AR, Melmed S, Schlechte J. Patient guide to hyperprolactinemia diagnosis and treatment. *J Clin Endocrinol Metab* 2011;96:35-6.
5. Purdie DW, Aaron JE, Selby PL. Bone histology and mineral homeostasis in human pregnancy. *Br J Obstet Gynaecol* 1988;95:849-54.
6. Lees CJ, Jerome CP. Effects of pregnancy and lactation on bone in cynomolgus macaques: histomorphometric

Figure 1. Levels of osteoprotegerin in the mother's blood according to weeks of pregnancy. The increase clearly occurs in the second half of pregnancy, since, as seen in panel A, there is no difference between blood levels in a woman who is not pregnant and those in a woman who has been pregnant for up to 18 weeks. Panel B shows that there is an increase as the pregnancy progresses, but the slope of the line of best fit is considerably lower than that of the known curves for the increase in estrogens or prolactin (data not shown). Taken from citation 21, with the permission of Elsevier)



7. Møller UK, Strem S, Mosekilde L & Rejnmark L. Changes in bone mineral Q17 density and body composition during pregnancy and postpartum. A controlled cohort study. *Osteoporos Int* 2012;23:1213-23.
8. Kraemer B, Schneider S, Rothmund R, Fehm T, Wallwiener D, Solomayer EF. Influence of pregnancy on bone density: a risk factor for osteoporosis? Measurements of the calcaneus by ultrasonometry. *Arch Gynecol Obstet* 2012;285:907-12.
9. Møller UK, Strem S, Mosekilde L, Heickendorff L, Flyvbjerg A, Frystyk J, et al. Changes in calcitropic hormones, bone markers and insulin-like growth factor I (IGF-I) during pregnancy and postpartum: a controlled cohort study. *Osteoporos Int* 2013;24:1307-20.
10. Sato K. Hypercalcemia during pregnancy, puerperium, and lactation: review and a case report of hypercalcemic crisis after delivery due to excessive production of PTH-related protein (PTHrP) without malignancy (humoral hypercalcemia of pregnancy). *Endocr J* 2008;55:959-66.
11. Turner M, Barré PE, Benjamin A, Goltzman D, Gascon-Barré M. Does the maternal kidney contribute to the increased circulating 1,25-dihydroxyvitamin D concentrations during pregnancy? *Miner Electrolyte Metab* 1988;14:246-52.

12. Holick MF. Vitamin D deficiency. *N Engl J Med* 2007; 357:266-81.
13. Karras SN, Anagnostis P, Annweiler C, Naughton DP, Petroczi A, Bili E, et al. Maternal vitamin D status during pregnancy: the Mediterranean reality. *Eur J Clin Nutr* 2014;68:864-9.
14. Sabonet L, Tarín JJ, Hervás A, Sanz-Salvador L, Ortiz E, Cano A. Efecto del tratamiento con vitamina D en el desarrollo óseo del fémur fetal. *Rev Osteoporos Metab Miner* 2013;5:5.
15. Viljakainen HT, Saarnio E, Hytinen T, Miettinen M, Surcel H, Mäkitie O, et al. Maternal vitamin D status determines bone variables in the newborn. *J Clin Endocrinol Metab* 2010;95:1749-57.
16. Fudge NJ, Woodrow JP, Kovacs CS. Pregnancy rescues low bone mass and normalizes intestinal calcium absorption in Vdr null mice. *J Bone Miner Res* 2006;21(Suppl):S52.
17. Sheng MH, Lau KH, Baylink DJ. Role of osteocyte-derived Insulin-Like Growth Factor I in developmental growth, modeling, remodeling, and regeneration of the bone. *J Bone Metab* 2014;21:41-54.
18. Baumann GP. Growth hormone isoforms. *Growth Horm IGF Res* 2009;19:333-40.
19. Handwerger S, Freemark M. The roles of placental growth hormone and placental lactogen in the regulation of human fetal growth and development. *J Pediatr Endocrinol Metab* 2000;13:343-56.
20. Prolactin directly enhances bone turnover by raising osteoblast-expressed receptor activator of nuclear factor kappaB ligand/osteoprotegerin ratio. *Bone* 2008;42:535-46.
21. Hong JS, Santolaya-Forgas J, Romero R, Espinoza J, Gonçalves LF, Kim YM, et al. Maternal plasma osteoprotegerin concentration in normal pregnancy. *Am J Obstet Gynecol* 2005;193:1011-5.
22. Lonergan M, Aponso D, Marvin KW, Helliwell RJ, Sato TA, Mitchell MD, et al. Tumor necrosis factor-related apoptosis-inducing ligand (TRAIL), TRAIL receptors, and the soluble receptor osteoprotegerin in human gestational membranes and amniotic fluid during pregnancy and labor at term and preterm. *J Clin Endocrinol Metab* 2003;88:3835-44.
23. Briana DD, Boutsikou M, Baka S, Hassiakos D, Gourgiotis D, Malamitsi-Puchner A. Circulating osteoprotegerin and sRANKL concentrations in the perinatal period at term. The impact of intrauterine growth restriction. *Neonatology* 2009;96:132-6.
24. Dorota DK, Bogdan KG, Mieczyslaw G, Bozena LG, Jan O. The concentrations of markers of bone turnover in normal pregnancy and preeclampsia. *Hypertens Pregnancy* 2012;31:166-76.
25. Yang MJ, Tseng JY, Chen CY, Yeh CC. Changes in maternal serum insulin-like growth factor-I during pregnancy and its relationship to maternal anthropometry. *J Chin Med Assoc* 2013;76:635-9.
26. Godang K, Frøslie KF, Henriksen T, Isaksen GA, Voldner N, Lekva T, et al. Umbilical cord levels of sclerostin, placental weight, and birth weight are predictors of total bone mineral content in neonates. *Eur J Endocrinol* 2013;168:371-8.
27. Baird J, Kurshid MA, Kim M, Harvey N, Dennison E, Cooper C. Does birthweight predict bone mass in adulthood? A systematic review and meta-analysis. *Osteoporos Int* 2011;22:1323-34.
28. Murphy VE, Smith R, Giles WB, Clifton VL. Endocrine regulation of human fetal growth: the role of the mother, placenta, and fetus. *Endocr Rev* 2006;27:141-69.
29. Mahon P, Harvey N, Crozier S, Inskip H, Robinson S, Arden N, et al; SWS Study Group. Low maternal vitamin D status and fetal bone development: cohort study. *J Bone Miner Res* 2010;25:14-9.

Díaz Curiel M

Enfermedades Metabólicas Óseas/Servicio de Medicina Interna II - Fundación Jiménez Díaz - Madrid

Action of vitamin K on bone health

Correspondence: Manuel Díaz Curiel - Policlínica A de Medicina Interna - Fundación Jiménez Díaz - Avda. Reyes Católicos, 2 - 28040 Madrid (Spain)
e-mail: mdcuriel@fjd.es

Date of receipt: 23/12/2014

Date of acceptance: 02/02/2015

Summary

Objetives: Nowadays it is recognised that vitamin K plays an important role in bone health. It is necessary for the gamma-carboxylation of osteocalcin (the most important non-collagen protein in the bone), making the osteocalcin function. There are two important forms of vitamin K (vitamin K1 and vitamin K2), which come from different sources and have different biological activity.

Epidemiological studies suggest that a diet with high levels of vitamin K is associated with a lower risk of hip fractures in older men and in women. However, controlled randomised clinical trials, carried out with supplements of vitamin K1 or K2 in the white population do not show an increase in bone mineral density (BMD) in most of the different areas of the skeleton. Supplementation with vitamin K1 and K2 may reduce the risk of fracture, but the clinical trials which include fractures as a final result have methodological limitations, so clinical trials with greater numbers of patients, and which are better designed, would be needed in order to prove the efficacy of vitamin K1 and K2 in relation to fractures.

In conclusion, we may say that there is currently insufficient evidence to recommend the routine use of vitamin K for the prevention of osteoporosis and fractures in postmenopausal women.

Key words: *bone mineral density, fractures, menaquinones, osteoporosis, phylloquinones, vitamin K.*

Introduction

In the last two decades the use of nutritional supplements for the prevention of diseases has increased significantly in the developed nations. Calcium and vitamin D are the two main supplements used to achieve better bone health. There is also much interest in vitamin K. Vitamin K is better known for its functions in blood coagulation, but it is also important in bone metabolism.

We have carried out a review of the different forms and sources of vitamin K and its effects on bone mineral density (BMD) and on fractures.

Forms and dietary sources of vitamin K

The term vitamin K represents a group of liposoluble compounds, chemically similar, which differ in their origins and/or their functions. There are two natural forms of vitamin K: vitamin K1 and vitamin K2. Vitamin K1, also called phyloquinone or phytonadione, is synthesised by the plants and is the predominant form of vitamin K in the human diet¹. Its main sources are green-leafed vegetables (e.g. watercress, parsley, cabbage, spinach, lettuce), vegetables of the genus *brassica* (e.g. Brussels sprouts, broccoli), some fruits (e.g. avocado, kiwi fruit and white grapes), some herbs (e.g. parsley and coriander) and green or herbal teas. Other dietary sources are vegetable oils such as soya or olive, these being the supplements which are the most bioavailable¹. It is also found in liver, butter and minced beef.

Vitamin K2 includes a range of forms of vitamin K known as menaquinones-n (MK-n), where the n refers to the number of repeated units of 5-carbon. The principal menaquinones in the diet range from MK-4 to MK-10, and are mainly consumed in foods which contain fats, which favours its absorption and bioavailability over phyloquinone 2. The menaquinones are produced especially by bacteria, except MK-4 (or menatetrenone). In spite of its low bioavailability in foods, MK-4 is the predominant form of vitamin K in the body. For this reason, some scientists suggest that MK-4 is produced through the endogenous conversion of the endogenous phyloquinones as well as MK-7, -8 and -9². MK-4 may also be found in fish, eggs, liver, kidney, milk, butter, fermented cheeses and some vegetables. The quantity and types menaquinones in fermented products depend on the type of bacteria present in those products. Natto, a Japanese condiment of fermented soya is the richest dietary source of menaquinones (especially MK-7) currently known. The menaquinones with the longest chains (MK-10 to MK-13) are produced by the anaerobic bacteria of the colon, but have very low bioavailability and little activity, like vitamin K^{1,2}. MK-7 is the form which has the highest bioavailability and longest half-life compared with the phyloquinones and MK-4³.

Vitamin K in the diet is absorbed in the small intestine through a process which requires the presence of bile salts. After intestinal absorption, the vitamins K1 and K2 are transported in lipoproteins rich in triglycerides (chylomicrons) through the lymphatic system towards the liver and other

tissues. The vitamin K1 is primarily captured by the liver to be metabolized and excreted¹. A small proportion of vitamin K1, which returns to the circulation in particles of lipoproteins with very low density secreted by the liver, is transported to the extra-hepatic tissues¹. The menaquinones are transported by means of low density lipoproteins from the liver to the extra-hepatic tissues, such as the bone. The exception is MK-4, which is transported by both low and high density lipoproteins. Vitamin K1 and the long chain menaquinones are stored, essentially, in the liver, while MK-4 is stored predominantly in the brain, the reproductive organs, the pancreas and the glands¹.

Dietary recommendations

Only a small quantity of vitamin K is accumulated in the body². Although some studies have reported functions of vitamin K beyond its action in coagulation, as well as its role in bone metabolism, the Institute of Medicine has established that the daily recommended intake (DRI) for an adequate intake (AI) for men and women is based on the absence of abnormal haemorrhages⁴. The AI for vitamin K1 is 120 µg/day for men and 90 µg/day for women¹. Due the absence of known toxicity, an upper limit has not been established for vitamin K1⁴. Recent studies have suggested that vitamin K2 may be more biologically active than vitamin K1², but due to the lack of sufficient data to date the Institute of Medicine has not provided DRI values for vitamin K2.

Vitamin K deficiency

Deficiency in vitamin K may occur as a result of diseases of the liver, pancreatic or biliary disease, cystic fibrosis, diseases of malabsorption of fats, ulcerous colitis, regional enteritis or Crohn's disease, short intestine syndrome and intestinal surgery (especially of the terminal ileum where the biliary salts are absorbed), chronic malnutrition, alcoholism, and the taking of medicines such as anticoagulants antagonistic to vitamin K⁵. Deficiency in vitamin K increases the risk of bleeding and may have deleterious effects on bone health.

Vitamin K supplements

Vitamin K1, MK-4 and MK-7 are available in pharmacological forms. Vitamin K1 is the most common form of vitamin K commercially available, referred to as phytonadione. Vitamin K1 supplements are used to treat and prevent vitamin K deficiency, to prevent haemorrhages or problems of coagulation caused by certain medicines or diseases and to counteract the effects of an overdose of anticoagulants. Dietary supplements of MK-4 and MK-7 have been approved in Japan for the prevention and treatment of osteoporosis⁶. Menadione or "vitamin K3" is a synthetic hydrosoluble form of vitamin K which may be converted into vitamin K2 in the body. The US Food and Drugs Administration has not authorised menadione to be sold as a dietary supplement for humans due to its potential deleterious effects⁵.

Vitamin K and bone metabolism

Vitamin K is the essential co-factor for the gamma-carboxylation of proteins with gamma-carboxyglutamic (Gla) residues, facilitating the posttranslational conversion of glutamic acid (Glu) to Gla residues in the proteins dependent on vitamin K and activating them. It is involved in the regulation of the management of calcium in the body. Although vitamin K prevents vascular calcification and that of the soft tissues, it also promotes the integration of calcium into bone.

There are three vitamin K-dependent proteins in the bone: osteocalcin (also called bone Gla protein), Gla matrix protein and protein S. The effect of vitamin K on osteocalcin is perhaps the best understood of these.

Osteocalcin is synthesised by the osteoblasts during the mineralisation phase of bone formation and is essential for the formation of crystals of hydroxyapatite. Glu has three residues, and their capacity to bond to mineral depends on gamma-carboxylation which is dependent on vitamin K. Although the vitamin K-dependent coagulation factors are 100% gamma-carboxylated, as they are found in dietary recommendations for their use, more than 40% of blood osteocalcin may be non-carboxylated. It has been shown that supplements with either MK-4 or MK-7 already produce a level of carboxylation similar to osteocalcin². However, supplementation with MK-7 appears to be more effective in carboxylating osteocalcin than supplementing with phylloquinones².

In addition to the gamma-carboxylation of osteocalcin vitamin K may affect the genetic transcription required for the expression of the osteoblast markers and thus affect the synthesis of collagen⁷. Furthermore, vitamin K may also suppress bone resorption and osteoclastogenesis^{8,9}. *In vitro* and in animal studies, it has been suggested that MK-4 may be associated with the regulation of inflammation, oxidative stress and apoptosis¹⁰, all of which may reduce bone resorption. In a study carried out in osteoblasts, it was observed that MK-7 suppresses the differentiation of osteoblasts and induces the mRNA of osteocalcin, osteoprotegerin and RANKL¹¹.

Also, vitamin K2 may act on bone through a function which regulates transcription, inducing the expression of the gene for the steroid and xenobiotic receptor (SXR), which is expressed primarily in the liver and the intestine, regulating the expression of the cytochrome P450 enzymes (CYP3A4 and CYP2C8) and of the family of ATP transporters such as MDR1 and MRP2. Vitamin K modulates the expression of osteoblast bone markers through SXR, favouring bone formation, which means that SXR is probably also involved in the maintenance of bone homeostasis¹².

Association between vitamin K and BMD and fractures: observational studies

In the majority of observational studies low blood levels of vitamin K1, low intake of vitamin K1, low intake of vitamin K2 (MK-7) and high blood levels of non-carboxylated osteocalcin have been asso-

ciated with an increased risk of hip fractures¹³⁻¹⁵. For example, in the Nurses' Health Study, carried out in women between 30 and 88 years of age (n=72,327), those with an intake of phylloquinones lower than 109 µg/day had an increased risk of fracture at 10 years compared with those who had a higher intake of phylloquinones¹⁶. Similarly in the Framingham Heart Study, in a group of 888 men and women with an average of age 75 years and an average intake of phylloquinone of 56 µg/day, it was observed that they had a higher risk of fracture of the hip in the following seven years than those who ingested an average of 254 µg/day. In this study there was no association between the intake of vitamin K and BMD¹⁷.

Although few studies have shown, overall, an association between a low intake of vitamin K and a reduction in BMD in women, there is less evidence of an association between high levels of vitamin K intake and an increase in BMD in observational studies¹⁴. These studies suggest: that an adequate intake of vitamin K may be necessary to reduce bone resorption; that the requirements for the maintenance of adequate bone health should be higher than the adequate intake values proposed; and that, once the vitamin K requirements for bone health are reached no additional intake is needed. In addition, a greater limitation of these studies is that high intakes of vitamin K1 may be an indicator of the consumption of foods which contain other nutrients protective of bone, such as calcium, magnesium, potassium and phytochemicals. Therefore, on the basis of the findings of the observational studies, we cannot conclude that vitamin K has an independent protective effect on bone health.

Effects of the supplementing of vitamin K on BMD and on fractures: clinical trials and meta-analyses

Various clinical trials in different populations have examined the effect of vitamin K on BMD. Two systematic reviews and meta-analyses have made a summary of these clinical trials^{18,19}. In the most recent review published in 2012, Fang et al.¹⁹ collect the data from 17 trials with vitamin K in the healthy population and in patients over 18 years of age with primary and secondary osteoporosis. These include ten trials with vitamin K2 (eight with MK-4 at a dose of 15-45 mg/day and two with MK-7 at a dose of 0.2-3.6 mg/day) and seven trials with vitamin K1 (0.2-10 mg/day). In the general analysis the authors mix the results of all the trials with vitamin K and examine the changes in BMD. They observe that supplementing with vitamin K had no effect on the BMD in the femoral neck, but increased the BMD in the lumbar spine by 1.3% (95% confidence interval [95% CI]: 0.5-2.1) after 6-36 months of supplementation¹⁹. In an analysis of subgroups according to type of vitamin K, vitamin K2 increased BMD in the lumbar spine by an average of 1.8% (95% CI: 0.9-2.8), while vitamin K1 had no effect. The therapeutic effect on BMD in the lumbar spine was much gre-

ater in Asiatic populations than in Western. However, when the authors excluded those studies with a high risk of methodological errors due to the existence of other factors, they found no significant effects of vitamin K in the lumbar region. Fang et al.¹⁹ warned against these estimated errors in the effects of treatment in the meta-analysis, due largely to the differences in the groups studied, differences in methodological quality in the trials selected and to errors in publications. The effect of the supplements of vitamin K2 on fractures is based on eight clinical trials carried out Japanese patients with primary and secondary osteoporosis.

A randomised clinical trial among 325 postmenopausal women who received a placebo or 45 mg/day of vitamin K2 (MK-4 or menatetrenone) over a period of three years²⁰, evaluated the bone mineral content (BMC) and the geometry of the hip using DXA. The indices of bone strength were calculated using DXA (BMD), femoral neck width (FNW) and femoral axis length (FAL). It was observed that vitamin K did not affect the BMD, but the BMC and FNW were increased in comparison to the placebo. In the group treated with vitamin K2 the bone strength in the hip did not vary, while it reduced significantly in the group treated.

A systematic review carried out in 2006 with a meta-analysis of seven clinical trials showed that supplementing with MK-4, 15-45 mg/day over 12-24 months, reduced significantly fractures of the hip (odds ratio [OR]: 0.23, 95% CI: 0.12-0.47) and vertebrae (OR: 0.40, 95% CI: 0.25-0.65), and non-vertebral fractures (OR: 0.19, 95% CI: 0.11-0.35)¹⁸. However, another major trial published in 2009, came to a different conclusion²¹. This was a wide, open trial in phase IV carried out in 4,378 Japanese osteoporotic women with or without prevalent vertebral fractures who received over three years supplements of MK-4 and calcium, with a year of follow up during which no kind of restriction in the use of medication for osteoporosis was imposed. The combined treatment with MK-4, 45 mg/day (divided into three doses of 15 mg each) and calcium, or the treatment with calcium only, was not associated with changes in the incidence of vertebral fractures after 3 year years (5.9% vs 5.7%) or in the incidence of all clinical fractures after 4 years (2.5% vs 2.1%). However, in one of the 11 non-adjusted groups, in a post-hoc analysis the researchers found a statistically significant reduction in the appearance of new vertebral fractures in a subgroup of women with more than five prevalent vertebral fractures (20.3% vs 33.2%, $p=0.03$).

More recently, a double blind randomised trial, carried out in 2013 with MK-7 compared with a placebo over 3 years in 244 postmenopausal Dutch women without osteoporosis found one woman with a new vertebral fracture in the MK-7 group ($n=120$) and six in the placebo group ($n=124$)²², but there were too few fractures for the difference to be statistically significant between the two groups.

Examining all the literature published to date, vitamin K2 supplements may protect against fractures but the data are not very consistent.

The evidence of the effect of supplementation with vitamin K1 on fractures is more limited, and based principally on a single study⁶, since the rest of the trials with vitamin K1 were not designed to analyse fractures. This study is a controlled, randomised double blind clinical trial carried out in 440 postmenopausal Canadian women with osteopenia. It showed a statistically significant effect with the administration of vitamin K1, 5 mg/day, in reducing all fractures after 2-4 years of supplementation (9 women with 11 fractures in the group treated with vitamin K1 vs 20 women with 21 fractures in the placebo group [hazard ratio 0.48, 95% CI 0.20-0.98]), although the fracture was a secondary result of the trial.

Effects of vitamin K supplements associated with other agents for the treatment of osteoporosis

There have been few studies carried out which compare the possible additive effects of vitamin K on the bone of patients being treated for osteoporosis. A Japanese group²³ has studied the effects of risedronate, alone or associated with vitamin K2, on the levels of carboxylated or non-carboxylated osteocalcin (OC). They observed that there was no difference in the levels of OC between the groups, but those patients with vertebral fractures had levels of non-carboxylated OC higher than those patients without fractures in the group treated only with risedronate.

Another group of Japanese authors²⁴ studied the effect of alendronate associated, or not, with vitamin K2 in postmenopausal women with rheumatoid arthritis. In a study of 62 patients with osteopenia or osteoporosis, those with low levels of non-carboxylated OC were treated with alendronate plus vitamin K2, and those who had normal levels, only with alendronate. After a year of treatment the levels of bone markers (alkaline phosphatase and N-terminal telopeptide of collagen I) decreased equally in both groups. There was no difference in the changes in bone mass in the lumbar spine between the two groups, but there was a statistically significant increase in the BMD in the femoral neck in the group supplemented with vitamin K.

Methodological limitations of the current evidence

The differences in the findings of the various studies on the effect of vitamin K on the BMD and on fractures may be explained by the different forms of vitamin K used, by the underlying intake of vitamin K of each of the groups, by the level of intake of calcium and vitamin D in each of the groups, or by differences in the populations studied. For example, the Japanese studies use MK-4 as vitamin K2, and the European studies use MK-7, while North American studies mainly use vitamin K1. The Japanese clinical trials with MK-4 had

various problems in their methodology, such as a lack of blind studies, high rates of abandonment and lack of randomisation. The participants of these studies were older, with primary or secondary osteoporosis, possibly with low levels of vitamin D and with a poor calcium intake, and with a high underlying risk of fracture. For these reasons, it is not possible to generalise these results with those obtained in trials with MK-4 carried out in healthy postmenopausal women with normal levels of vitamin D and an acceptable intake of calcium. Furthermore, no studies have been carried out with vitamin K supplements in which fractures were considered to be the principal outcome. Therefore, we cannot make a definitive conclusion as to the overall effect of vitamin K supplements on the prevention of fractures.

Safety and adverse effects of vitamin K supplements

Vitamin K supplements are well-tolerated and safe in most cases. Some studies have reported rare effects of supplementation with MK-4 (menatetrenone), such as the incidence of skin lesions and minor gastro-intestinal effects⁵. A few studies have shown that supplements with vitamin K1 may affect the lipid profile, sensitivity to insulin and levels of glycemia⁵.

Vitamin K may reduce the effect of anticoagulants such as warfarin. People who take warfarin should be warned to avoid supplements and foods which may contain vitamin K. There have also been reported interactions with antilipemics and antidiabetics⁵.

Problems of knowledge and future research

It has been proposed that the non-carboxylation of osteocalcin adversely affects its capacity to bond with the bone mineral. However, those studies carried out in which an adequate or maximum level of carboxylated osteocalcin was achieved, did not correspond with an improvement in BMD. It is possible that the effects of vitamin K on BMD may be more pronounced in those populations which have osteoporosis or those with a vitamin D deficit, since there is an interaction between vitamin K and vitamin D.

There is also no effect observed of vitamin K on BMD in subjects with adequate levels of vitamin K. It is probable that the effects of vitamin K on BMD are more positive in those subjects with a vitamin K deficit, such as those with malnutrition or affected by diseases which interfere with its synthesis or absorption.

In spite of the minimal effects on BMD, vitamin K may have a protective effect against fractures. It is possible that vitamin K exerts its effect through the carboxylation of the GLA protein of the matrix, an effect which is not detected in the measurement of BMD. In addition to the role vitamin K plays in gamma-carboxylation there are other mechanisms in the bone which are dependent on vitamin K and which may affect the risk of fracture. For example, the effect of vitamin K on

fractures may be mediated through its effects on bone quality, geometry or strength^{6,20}. Further studies would be needed to clarify these points.

In conclusion, vitamin K is important for bone health. A low intake of vitamin K, low blood levels of the vitamin or high levels of non-carboxylated osteocalcin are associated with an increase in hip fractures in the observational studies¹³. However, the results of the clinical trials are not conclusive, raising doubts as to whether or not general supplementation with vitamin K1 or K2 reduces the risk of vertebral or non-vertebral fractures. It is likely that carrying out new studies in populations with low blood levels, or a low intake, of vitamin K could clarify the role of vitamin K in the prevention of fractures²⁵.

Bibliography

1. Booth SL, Suttie JW. Dietary intake and adequacy of vitamin K. *J Nutr* 1998;128:785-8.
2. Beulens JW, Booth SL, van den Heuvel EG, Stoeklin E, Baka A, Vermeer C. The role of menaquinones (vitamin K2) in human health. *Br J Nutr* 2013;110:1357-8.
3. Sato T, Schurgers LJ, Uenishi K. Comparison of menaquinone-4 and menaquinone-7 bioavailability in healthy women. *Nutr J* 2012;11:93.
4. Food and Nutrition Board, Institute of Medicine. Dietary reference intakes for vitamin A, vitamin K, arsenic, boron, chromium, copper, iodine, iron, manganese, molybdenum, nickel, silicon, vanadium, and zinc. Washington DC: The National Academies Press; 2001.
5. Natural Standard. Vitamin K-Professional Monograph. Available at: <http://www.naturalstandard.com/databases/vitamink>. Accessed May 31, 2013.
6. Cheung AM, Tile L, Lee Y, Tomlinson G, Hawker G, Scher J, et al. Vitamin K supplementation in postmenopausal women with osteopenia (ECKO trial): a randomized controlled trial. *PLoS Med* 2008;5:e196.
7. Ichikawa T, Horie-Inoue K, Ikeda K, Blumberg B, Inoue S. Steroid and xenobiotic receptor SXR mediates vitamin K2-activated transcription of extracellular matrix-related genes and collagen accumulation in osteoblastic cells. *J Biol Chem* 2006;281:16927-34.
8. Booth SL. Roles for vitamin K beyond coagulation. *Annu Rev Nutr* 2009;29:89-110.
9. Iwamoto J, Sato Y, Takeda T, Matsumoto H. High-dose vitamin K supplementation reduces fracture incidence in postmenopausal women: a review of the literature. *Nutr Res* 2009;29:221-8.
10. Suttie JW, Booth SL. Vitamin K. *Adv Nutr* 2011;2:440-1.
11. Katsuyama H, Otsuki T, Tomita M, Fukunaga M, Fukunaga T, Suzuki N, et al. Menaquinone-7 regulates the expressions of osteocalcin, OPG, RANKL and RANK in osteoblastic MC3T3E1 cells. *Int J Mol Med* 2005;15:231-6.
12. Tabb MM, Sun A, Zhou G, Grün F, Errandi J, Romero K, et al. Vitamin K2 regulation of bone homeostasis is mediated by the steroid and xenobiotic receptor SXR. *J Biol Chem* 2003;278:43919-27.
13. Shea MK, Booth SL. Update on the role of vitamin K in skeletal health. *Nutr Rev* 2008;66:549-57.
14. Vermeer C. Vitamin K: the effect on health beyond coagulation—an overview. *Food Nutr Res* 2012;56:5329.
15. Hodges SJ, Akesson K, Vergnaud P, Obrant K, Delmas PD. Circulating levels of vitamin K1 and K2 decreased in elderly women with hip fracture. *J Bone Miner Res* 1993;8:1241-5.
16. Feskanich D, Weber P, Willett WC, Rockett H, Booth SL, Colditz GA. Vitamin K intake and hip fractures in women:

- a prospective study. *Am J Clin Nutr* 1999;69:74-9.
17. Booth SL, Tucker KL, Chen H, Hannan MT, Gagnon DR, Cupples LA, et al. Dietary vitamin K intakes are associated with hip fracture but not with bone mineral density in elderly men and women. *Am J Clin Nutr* 2000;71:1201-8.
 18. Cockayne S, Adamson J, Lanham-New S, Shearer MJ, Gilbody S, Torgerson DJ. Vitamin K and the prevention of fractures: systematic review and meta-analysis of randomized controlled trials. *Arch Intern Med* 2006;166:1256-61.
 19. Fang Y, Hu C, Tao X, Wan Y, Tao F. Effect of vitamin K on bone mineral density: a meta-analysis of randomized controlled trials. *J Bone Miner Metab* 2012;30:60-8.
 20. Knappen MH, Schurges LJ, Vermeer C. Vitamin K2 supplementation improves hip bone geometry and bone strength indices in postmenopausal women. *Osteoporos Int* 2007;18:963-72.
 21. Inoue T, Fujita T, Kishimoto H, Makino T, Nakamura T, Nakamura T, et al. Randomized controlled study on the prevention of osteoporotic fractures (OF study): a phase IV clinical study of 15-mg menatetrenone capsules. *J Bone Miner Metab* 2009;27:66-75.
 22. Knappen MH, Drummen NE, Smit E, Vermeer C, Theuvsissen E. Three-year low-dose menaquinone-7 supplementation helps decrease bone loss in healthy postmenopausal women. *Osteoporos Int* 2013;24:499-507.
 23. Kassukawa Y, Miyakoshi N, Ebina T, Aizawa T, Hongo M, Ishikawa Y, et al. Effects of risedronate alone or combined with vitamin K2 on serum undercarboxylated osteocalcin and osteocalcin levels in postmenopausal osteoporosis. *J Bone Miner Metab* 2014;32:290-7.
 24. Suzuki K, Tsuji S, Fukushima Y, Nakase T, Hamada M, Tomita T, et al. Clinical results of alendronate monotherapy and combined therapy with menatetrenone (VitK₂) in postmenopausal RA patients. *Mod Rheumatol* 2013;23:450-3.
 25. Iwamoto J. Vitamin K2 therapy for postmenopausal osteoporosis. *Nutrients* 2014;6:1971-80.